

# Computer Aided Rib Suppression on Chest Radiographs

Manjunath Babu P<sup>1</sup>, Pallavi<sup>2</sup>, Shalabh<sup>3</sup>, Roohullah Yasini<sup>4</sup>, Vivek kumar<sup>5</sup>  
<sup>1,2,3,4,5</sup> *BMSIT Bangalore*

**Abstract-** Computer aided diagnosis (CAD) system assist the doctors in several diagnostic tasks , one of them could be lung lesion detection. A major difficulty in the analysis of chest radiographs is due to invisibility of abnormalities caused due to superimposition of rib cage shadow on main lung tissue which is to be examined. Suppressing the rib cage shadow over lung tissue with no much medical information loss would therefore be helpful for the doctors to manually identify the abnormality such as lung nodules and hence save reasonable amount of time. The presence of rib cage shadow over lung tissue, often proves to be obstacle for visibility of nodules and further analysis of lung. Use of reasonable model of simple cells in mammalian vision system such as Gabor Filter helps to extract most of the ribcage features followed by enhancement of image contrast and manual segmentation of lung area. Enhancement of image contrast is carried out by using CLAHE method. This project demonstrates the process of computer aided ribcage shadow suppression with the help of Gabor filter.

**Index Terms-** CLAHE method, Enhancement of image contrast, Gabor filter, Lung segmentation, Morphological filter

## I. INTRODUCTION

Chest x-ray (Radiograph) is most commonly preferred test as screening test for diagnosis of abnormalities in chest.

A chest x-ray produces images of lungs, heart, and bones of spinal cord, airways, blood vessels and chest. The first and mandatory step of a computer aided diagnosis is to segment the lung as it is the main area of medical analysis.

Lung segmentation essentially involves isolation of lung area from spinal cord and heart which are not the part of Lung area to be examined. The lung lesions present on the lung may go un-noticed or suppressed due to the presence of ribcage shadow over it. Therefore, in computer aided diagnosis system it becomes necessary to suppress or eliminate the rib cage shadow over the lung field. On the other

hand, there are several reasons why automated analysis of chest radiographs can benefit from suppression of bony structures. A study showed that many lung lesions that are missed on radiographs are located behind the ribs, and suppression of which improves detection of lung nodules. The proposed methodology uses images of standard JSRT database for analysis and we describe about Gabor filter which is used for rib suppression.

## II. LITERATURE REVIEW

Jiann-Shu Lee et. al.[1] proposed non parametric-based rib suppression method for chest radiographs that uses active shape models for lung region extraction. By considering anatomical structures of rib cage they developed local sampling scheme to achieve non-parametric rib modeling. The scheme integrated knowledge based generalized Hough transform for accurate rib segmentation. By using Real Coded Genetic Algorithm (RCGA) the rib intensities are estimated and relative conspicuity of nodules is achieved followed by ribcage shadow suppression.

The authors in [2] proposed deep learning models for ribcage suppression on chest radiographs which uses multilayer convolutional neural networks. In this citation, they proposed two models viz., AE like encoder and CNN

Model where computational time for both models is different. Both models require pair of chest x-ray and their corresponding dual energy subtracted images. Rib suppressed images are achieved by introducing loss functions which look for multi-structural similarity in two images.

The authors in [3] proposed rib suppression method for enhancing frontal chest radiographs using independent component analysis (ICA) , ICA is used to find basis functions which represent bony structures as they are majorly counted in edge detection. In this method, ICA basis is created from

enhanced chest radiographs, clustering those basis and the chest x-ray is reconstructed with the help of non edge basis.

The authors in [4] proposed an x-ray CAD system with rib cage suppression for improved detection of lung lesions

That uses variety of filters such as constrained sliding band filter (CSBF), Large nodule filter (LNF) ,and outline area filter (OAF). Initially image is segmented, which includes separate segmentation of clavicles and rib cage, then the filters are used to improve nodule visibility and detect the nodules, the method also speaks about false positives reduction. Rib cage shadow is estimated using joint entropy and jaccard index which speaks about union of two regions.

The authors in [5] proposed fully automatic lung segmentation and rib suppression method for improving conspicuity of lung nodules in chest radiographs. This method uses models for automatic segmentation of lung and oriented spatial Gabor filter for rib cage suppression.

### III. PROPOSED METHOD

The proposed method describes rib cage shadow suppression on chest radiology in three different steps viz.,

Image enhancement, Lung segmentation, Rib cage shadow suppression

#### 1. IMAGE ENHANCEMENT:

The original image obtained from JSRT database has poor contrast level which calls for the usage of image enhancement technique. Here, we used contrast limited adaptive histogram equalization method for improving the contrast of image especially to make ribs more prominent. Since, intensity of pixels is discretely distributed on the image, CLAHE operates on small regions in the image called Tiles rather than entire image. Adapthisteq function calculates contrast transform function for each tile individually.

Each Tile's contrast is enhanced so, that the histogram of the output matches the histogram specified by distribution value. It uses uniform distribution by default.

#### 2. LUNG SEGMENTATION:

To maintain good amount of accuracy, the lung field is carefully extracted from the image manually by erasing the other parts such as spinal cord.

#### 3. RIBCAGE SHADOW SUPPRESSION:

For ribcage shadow suppression, we have to first obtain the ribcage for which the Gabor filter is introduced.

Gabor filters are a reasonable model of simple cells in mammalian vision system. Because of this, Gabor filters are thought to be good model of how humans distinguish texture and are therefore a useful model to use when distinguishing algorithm to recognize the texture.

#### GABOR FILTER:

Gabor filter named after Dennis Gabor, is a linear filter used for texture analysis i.e., it basically analyses whether there are any frequency contents in the image in specific direction. Choosing the parameters of Gabor filter proves to be difficult task as they play important role in extracting ribs. Gabor filter highlights the features or textures of image along with which it is oriented and suppresses rest all the features of image.

The expression for Gabor filter is given by,

$$g_{\lambda, \theta, \phi, \sigma, \gamma}(x, y) = e^{-\left(\frac{x'^2}{\sigma_x^2} + \frac{y'^2}{\sigma_y^2}\right)} \cdot \cos\left(2\pi \cdot \frac{x'}{\lambda} + \phi\right)$$

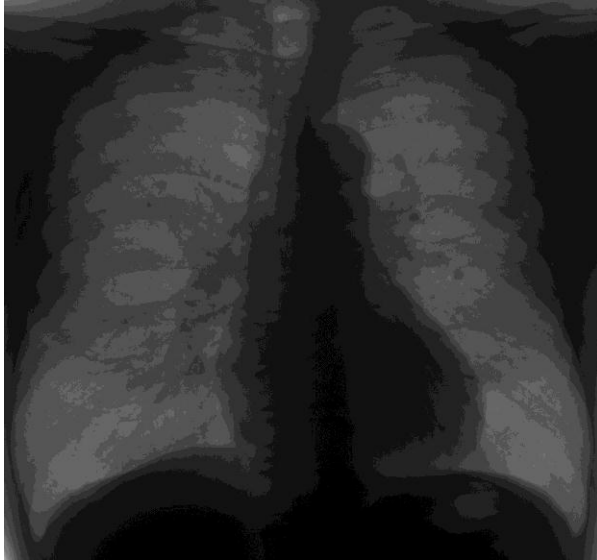Where,  $x' = x \cos \theta + y \sin \theta$

$$y' = -x \sin \theta + y \cos \theta$$

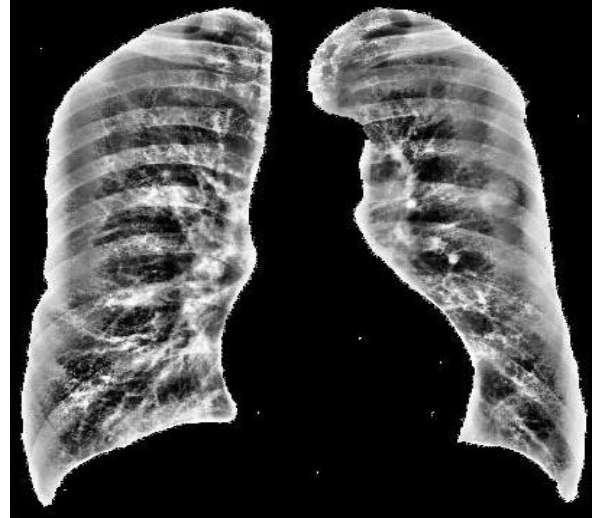Lambda ( $\lambda$ ) specifies cosine factor of Gabor function  
Theta ( $\theta$ ) specifies orientation of Gabor function  
Phi ( $\phi$ ) specifies phase offset of cosine factor  
Aspect ratio ( $\gamma$ ) specifies ellipticity of Gaussian factor

The enhanced image is first divided into two halves and each half is filtered by using Gabor filter with different orientation and then finally stitched into a single image. The reason behind image division is to make sure the desired frequency components are highlighted as the ribcage structure is quasi-parallel and structure on each side requires different orientation of Gabor filter.

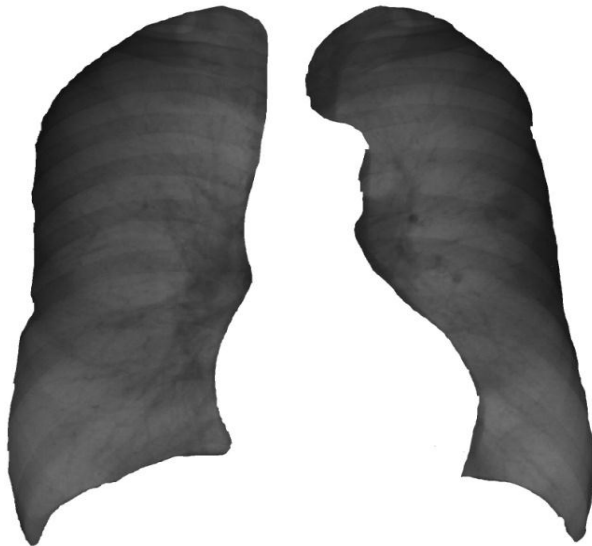### IV. EXPERIMENTATION AND RESULTS



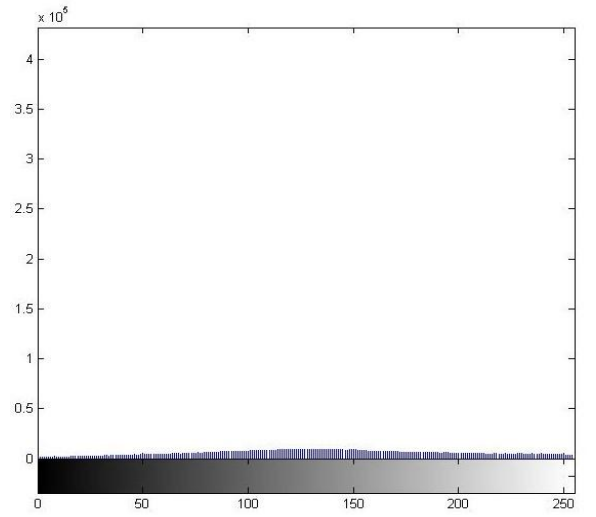
1. OriginalImage



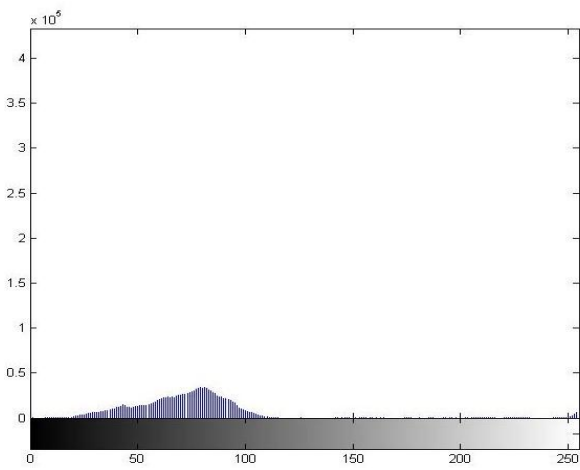
3.Enhanced image



2. Segmented image




5.Histogram of enhanced image




4.Histogram of original image

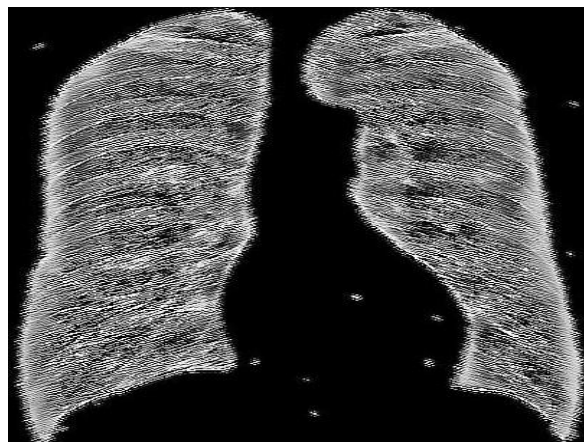
GABOR FILTER WITH DIFFERENT ORIENTATIONS



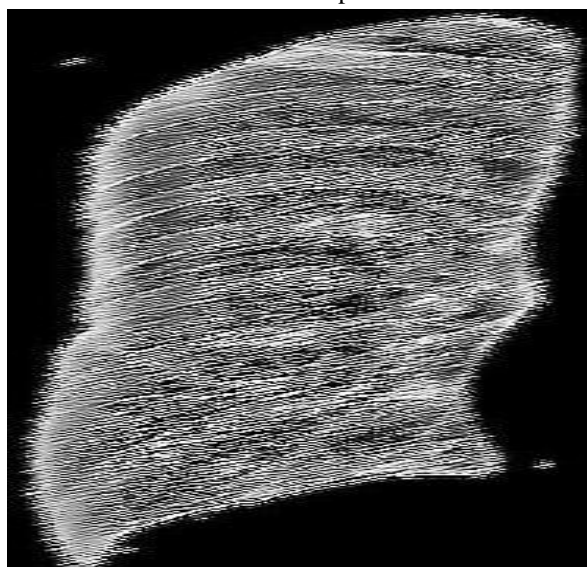
6. 110° oriented Gabor envelope



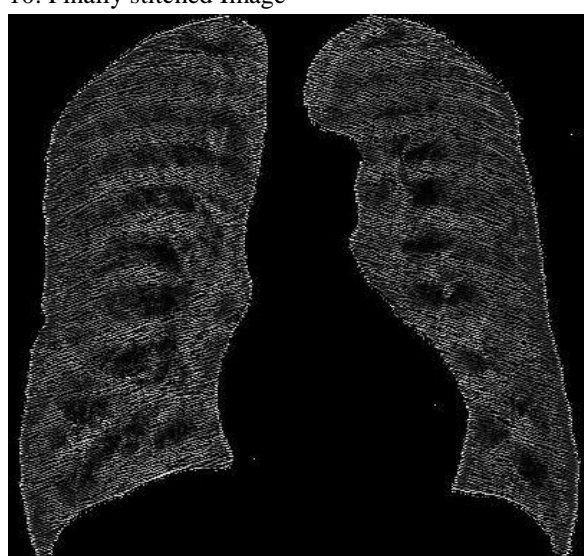7.  $-110^\circ$  oriented Gabor envelope



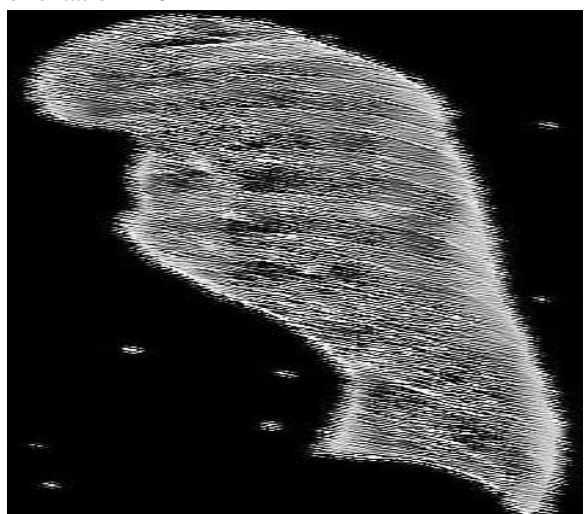
10. Finally stitched Image



8. Left halve of image filtered with Gabor with orientation  $110^\circ$



11. Image after subtracting ribs from Enhanced image



9. Right halve of image filtered with Gabor with orientation  $-110^\circ$

## V. CONCLUSION

In this paper, we presented the major application of Gabor filter for automatic extraction of ribcage rather than using a model to do so, thereby we obtain a relatively obscured image after subtracting it from enhanced image suppressing the ribs to certain extent. Gabor filters are used to make the whole process of extraction and suppression automatic, we wanted to avoid the use of techniques which use different models hence require human intervention to carry out the process. The impact of this technique on sensitivity of detecting lung nodules in chest radiographs will be investigated in a future observer performance study.

## REFERENCES:

- [1] J. Lee, J. Wang, H. Wu and M. Yuan, "A nonparametric-based rib suppression method for chest radiographs", *Computers & Mathematics with Applications*, vol. 64, no. 5, pp. 1390-1399, 2012. Available: 10.1016/j.camwa.2012.03.084.
- [2] B., T., M., A. and S., "Rib Suppression in Chest Radiographs Using ICA Algorithm", *Information Technology Journal*, vol. 6, no.7, pp. 1085-1089, 2007. Available: 10.3923/itj.2007.1085.1089.
- [3] Á. Horváth, G. Orbán, Á. Horváth and G. Horváth, "An X-ray CAD system with ribcage suppression for improved detection of lung lesions", *Periodica Polytechnica Electrical Engineering*, vol. 57, no. 1, p. 19, 2013. Available: 10.3311/ppee.2079.
- [4] C. Koehler, T. Wischgoll and F. Golshani, "3-D Reconstruction of the Human Ribcage Based on Chest X-Ray Images and Geometric Template Models", *IEEE MultiMedia*, pp. 1-1, 2019. Available: 10.1109/mmul.2009.57.
- [5] T. Satyasavithri and S. Devi, "Rib Suppression and Nodule Detection From Posterior and Anterior Chest Radiographs", *SSRN Electronic Journal*, 2019. Available: 10.2139/ssrn.3364906.
- [6] B. van Ginneken, "Deep Learning for Triage of Chest Radiographs: Should Every Institution Train Its Own System?", *Radiology*, vol. 290, no. 2, pp. 545-546, 2019. Available: 10.1148/radiol.2018182318.

#### About the authors

1. Manjunath babu P, is currently working as assistant professor in the department of Electrical & Electronics Engineering at BMSIT Bangaluru.
2. Pallavi, at present she is studying in the final year in department of Electrical and Electronics Engineering at BMSIT Bangaluru.
3. Shalabh, at present he is studying in the final year in department of Electrical and Electronics Engineering at BMSIT Bangaluru.
4. Roohullah Yasini, at present he is studying in the final year in department of Electrical and Electronics Engineering at BMSIT Bangaluru.
5. Vivek kumar, at present he is studying in the final year in department of Electrical and Electronics Engineering at BMSIT Bangaluru