

An Aberrant Origin of Dorsal Scapular Nerve from a Prefixed Brachial Plexus

Mrinmayee Deb Barma¹, Harshvardhan Ahlawat²

¹Society Of Clinical Anatomists (SOCA), MBBS, MD Anatomy, Assistant Professor, Department of Anatomy, Sri Lakshmi Narayana Institute of Medical Sciences (SLIMS), Pondicherry

²Asian Medical Student's Association (AMSA), Final year MBBS Student, Jawaharlal Institute of Post Graduate Medical Education and Research (JIPMER), Pondicherry,

Abstract: Dorsal scapular nerve takes its origin from the posterior aspect of C5 root. It then descends downwards and pierces the scalenus medius and passes backward, downward and laterally. It lies beneath the prevertebral fascia in the occipital triangle, it then disappears beneath the levator scapulae muscle to supply the rhomboids muscle. Dorsal scapular syndrome presents as an abnormal movement of the shoulder joint even though reduced movement. In this study we have reported the double origin of Dorsal scapular nerve in this manner is not so commonly found and the brachial plexus in our cadaver is prefixed type.

Key Words: Aberrant dorsal scapular nerve, Brachial plexus, Dorsal scapular nerve, Levator Scapulae

INTRODUCTION

Dorsal scapular nerve takes its origin from the posterior aspect of C5 root. It then descends downwards and pierces the scalenus medius and passes backward, downward and laterally. It lies beneath the prevertebral fascia in the occipital triangle, it then disappears beneath the levator scapulae muscle to supply the rhomboids muscle. We know that the brachial plexus is formed by the ventral rami of C5, C6, C7, C8 and T1. The prefixed type of brachial plexus is called when it gets the contribution from C4 whereas when it receives its contribution from T2 it is called the postfixed type. This type of variation is well documented in the textbooks of anatomy. Brachial plexus is a very complicated structure to understand. Embryologically, it is developed as an axon which outgrows from the spine into the arm bud. Knowledge of the plexus carries immense importance and popularity among the students, Anatomists, clinicians and surgeons. Brachial plexus block is a frequent practice among the

Anaesthetists; therefore any variation is helpful for them.

FINDINGS IN THE CADAVER

We found this variation in one male cadaver on the right side of neck among 10 cadavers and 20 sides of neck dissection during the routine dissection procedure on the formalin fixed cadavers. We followed the steps from the Cunningham's Manual of Practical Anatomy volume 3. The following structures were encountered during dissection: skin, superficial fascia containing the platysma muscle, external jugular vein, investing layer of deep cervical fascia and the cutaneous nerves emerging from the Erb's point or the nerve point approximately from the midpoint of the length of sternocleidomastoid muscle. We then removed the prevertebral fascia forming the facial carpet of the triangle and reflected the muscles forming the floor of triangle above downward: semispinalis capitis, splenius capitis, levator scapulae, scalenus posterior, medius, and anterior. Also, we found the inferior belly of omohyoid covered by the omohyoid fascia and 3 branches of supraclavicular nerves embedded in the fascia towards the clavicle. In between the scalenus medius and posterior three nerves are emerging out apart from the cervical plexus which provides the sensory innervation to the trapezius muscle. On further dissection, we separated the prevertebral fascia clearly and reflected the scalenus posterior in the deeper aspect, scalenus medius and levator scapulae clearly. A well-defined branch is taking origin from the posterior aspect of C5 which is found usually. Apart from this one more branch is emerging out from the posterior aspect of C5 and communicating with the C4 root. Then it descends downwards and is divided into smaller terminal branches within the substance of levator scapulae. Whereas the usual branch pierced the scalenus medius muscle and emerged from the scalenus

medius muscle and anterior to levator scapulae muscle. To achieve the clear visualisation of the findings, we made a horizontal incision on the scalenus medius muscle securing the dorsal scapular nerve. This branch is following the usual course of the nerve. Other findings, the phrenic nerve is taking the usual course in the region running vertically downward over the scalenus anterior muscle. The long thoracic nerve was also found. The nerve to subclavius arising from the anterior aspect is an usual finding. The type of formation of brachial plexus is prefixed here.

PICTURES

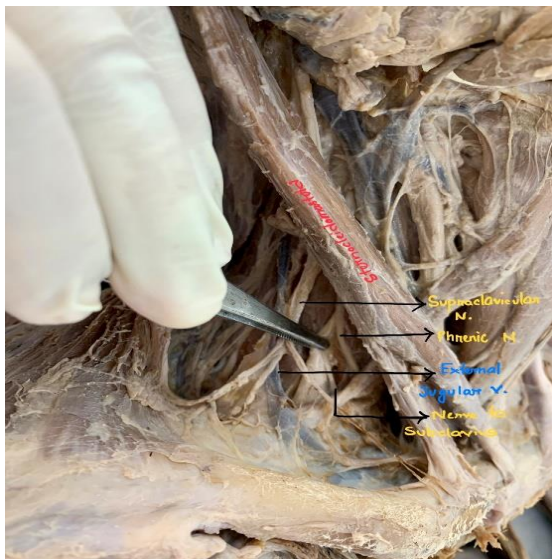


FIGURE 1: Showing the just after reflection of investing layer of deep cervical fascia. Sternocleidomastoid, Supraclavicular nerves: medial, intermediate and lateral branch, Phrenic nerve, External jugular vein, Nerve to subclavius

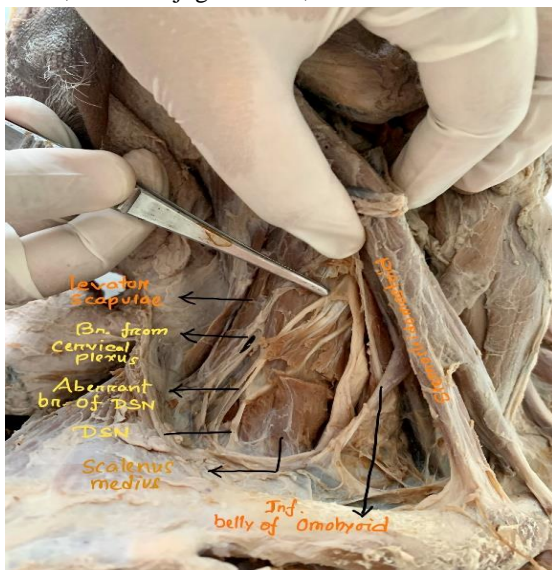


FIGURE 2: Showing the levator scapulae, sensory branch from the cervical plexus to the trapezius muscle, aberrant branch of dorsal scapular nerve, dorsal scapular nerve, scalenus medius, inferior belly of Omohyoid, sternocleidomastoid muscle.

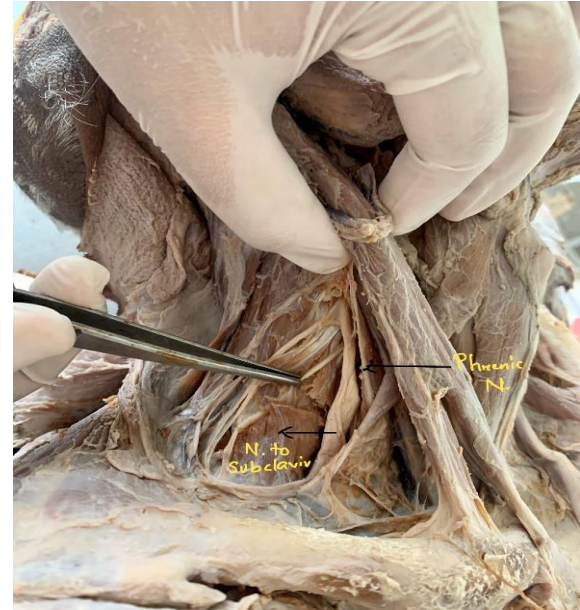

FIGURE 3: Showing phrenic nerve, nerve to subclavius

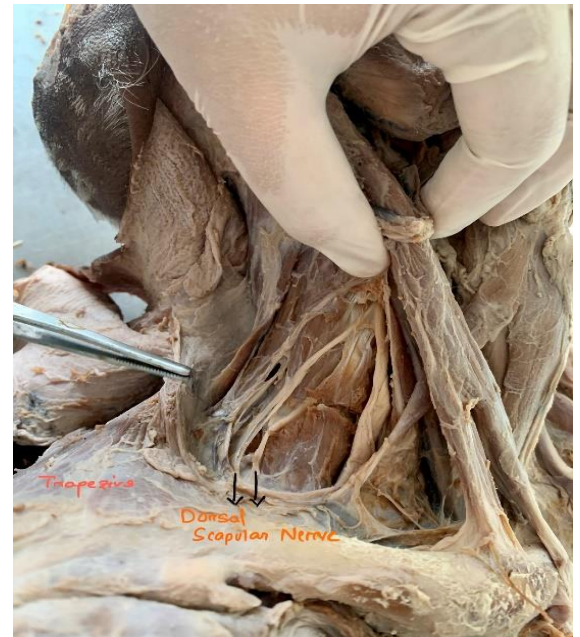

FIGURE 4: showing trapezius, dorsal scapular nerve

DISCUSSION

Dorsal scapular nerve supplies the levator scapulae, rhomboidus major and minor. Dorsal scapular syndrome presents as an abnormal movement of the shoulder joint even though reduced movement, localised Pain typically present on the shoulder joint resulting in winging of the scapula.

Lee HY et al (1992) documented a study in which 21.7% cases among 152 brachial plexuses were found to be prefixed.

Shilal P et al (2015) reported that the dorsal scapular nerve arose from C5 and got contributions from C5 & C6, the C5 component pierced the scalenus medius then C5 & C6 roots united and formed the main trunk of dorsal scapular nerve.

Nguyen V H et al (2016) documented that the Dorsal scapular nerve arose from C5 in around 70% cases and 25 % cases from C5 & C6.

In this study we have reported the double origin of Dorsal scapular nerve in this manner is not so commonly found and the brachial plexus in our cadaver is prefixed type.

CONCLUSION

Although our results are not to propose any change in the established clinical practice, such a variation may help the head and neck surgeons and clinicians. Furthermore, it can be useful in performing Ultrasound guided procedures and DSN blocks.

ACKNOWLEDGEMENT

We are heartily thankful to the noble souls for donating their bodies for the medical education and research purpose. We are thankful to the dissection hall staff for their support.

REFERENCE

- [1] Lee HY, Chung IH, Sir WS, Kang HS, Lee HS, Ko JS, Lee MS, Park SS. Variations of the ventral rami of the brachial plexus. *Journal of Korean medical science*. 1992 Mar 1;7(1):19-24.
- [2] Shilal P, Sarda RK, Chhetri K, Lama P, Tamang BK. Aberrant dual origin of the dorsal scapular nerve and its communication with long thoracic nerve: an unusual variation of the brachial plexus. *Journal of clinical and diagnostic research: JCDR*. 2015 Jun;9(6):AD01.
- [3] Nguyen VH, Liu HH, Rosales A, Reeves R. A cadaveric investigation of the dorsal scapular nerve. *Anatomy Research International*. 2016;2016.