A Silent Struggle: Rapid Neurodegeneration in Infantile Krabbe Disease – A Case Report

Dr Ankit Anand [1], Dr Arun Vannur[2]
1-Junior Resident, Department of Paediatrics, Jawaharlal Nehru Medical College, Belagavi,
2-Consultant, KLE Gokak

Abstract - Background: Krabbe disease is a rare autosomal recessive leukodystrophy caused by a deficiency of the galactocerebrosidase (GALC) enzyme, leading to progressive demyelination and neurodegeneration. Infantile Krabbe disease typically presents within the first six months of life with irritability, hypertonia, developmental regression, and optic atrophy.

Case Presentation:We report a case of a 6-month-old male infant who presented with increasing irritability, feeding difficulties, and progressive loss of motor milestones over two months. Clinical examination revealed hypertonia, spasticity, exaggerated deep tendon reflexes, and optic nerve atrophy. MRI of the brain showed characteristic leukodystrophic changes, and enzymatic analysis confirmed markedly reduced GALC enzyme activity. Despite supportive care, the infant exhibited rapid neurological decline, developing respiratory distress and bulbar dysfunction. The child succumbed to respiratory failure at 9 months of age.

Conclusion:Infantile Krabbe disease remains a devastating neurodegenerative disorder with limited treatment options. Early recognition through neuroimaging, enzyme assays, and genetic confirmation is crucial for diagnosis and counselling. Hematopoietic stem cell transplantation (HSCT) may offer potential benefits if initiated pre-symptomatically, emphasizing the need for newborn screening in at-risk populations.

INTRODUCTION

Krabbe disease, also known as globoid cell leukodystrophy, is a rare autosomal recessive disorder caused by mutations in the GALC gene, leading to deficient galactocerebrosidase enzyme activity. This deficiency results in the accumulation of psychosine, which is toxic to oligodendrocytes, causing widespread demyelination and progressive neurodegeneration. The infantile form, which is the most common and severe, typically presents within the first six months of life with irritability, hypertonia, feeding difficulties, developmental regression, and optic atrophy. Without intervention, affected infants usually experience rapid neurological decline and death within the first two years of life[1].

CASE PRESENTATION

A 6-month-old male infant was brought to the clinic with increasing irritability, poor feeding, and progressive loss of motor milestones over two months. The child was previously developing normally but began exhibiting abnormal movements and excessive crying.

CLINICAL DETAILS

On examination, the infant exhibited hypertonia, spasticity, exaggerated deep tendon reflexes, and optic atrophy. Neurological examination revealed global developmental delay, with significant impairment in motor functions. MRI of the brain demonstrated characteristic leukodystrophic changes, including periventricular and deep white matter hyperintensities[2].

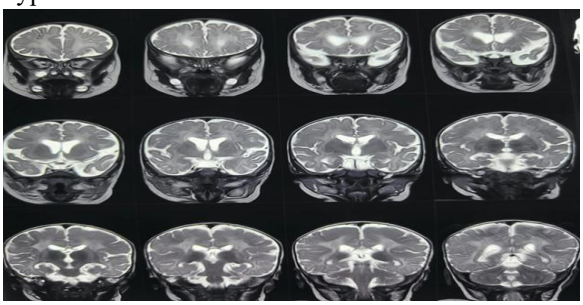

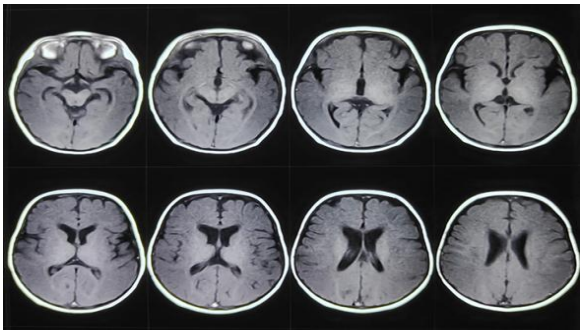

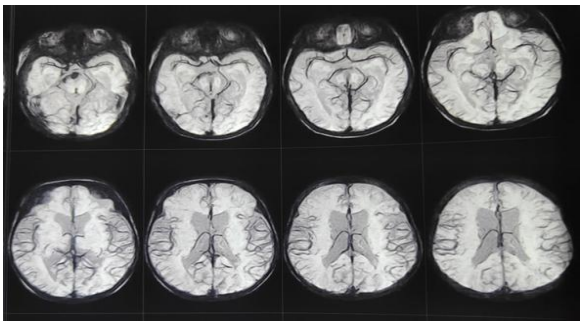

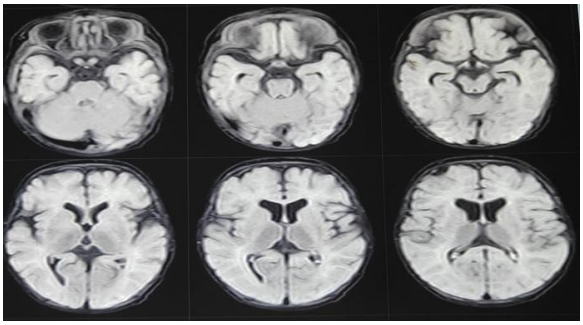

DIAGNOSIS

Enzymatic analysis confirmed significantly reduced GALC enzyme activity, consistent with Krabbe disease[3].

Lysosomal Enzymes Study From Leucocytes

ENZYMES	Result	Normal Range
Sulphatides β-Galactocerebrosidase (Krabbe Disease)	: 0.26	3.3 - 29.5 nmol/17 hrs/mg protein
Glycolipids and lipids β-Galactosidase (GM1 Gangliosidosis)	: 33.4	15.0 - 285.0 nmol/hr/mg protein

Remarks : Lysosomal enzyme study was carried out from leucocytes using specific synthetic substrate for β-galactocerebrosidase enzyme. β-Galactosidase was used as a reference enzyme. Hamdan has shown significantly reduced activity of β-galactocerebrosidase enzyme with normal activity of β-Galactosidase enzyme.
This suggests that Hamdan is highly likely to be affected with Krabbe disease.

LSD gene panel by smMIP is under process.

This is an autosomal recessive disorder with 25% risk in every pregnancy.
Prenatal diagnosis can be carried out at 12 to 16 weeks of gestation using enzymes or molecular study.

Ref.: Sheth JJ, Mistri M, Sheth FJ, Datar C, Godbole K, Kamate M, Patil K (2014). Prenatal diagnosis of Lysosomal Storage disorders by enzymes study using chorionic villus and amniotic fluid. J Fetal Med. 1: 17. doi:10.1007/s40556-014-0001-3.

TREATMENT

Supportive care, including physiotherapy and nutritional support, was initiated. However, due to the advanced stage of the disease at the time of diagnosis, the infant continued to deteriorate, developing respiratory distress and bulbar dysfunction.

MRI BRAIN PLAIN

REFERENCE: H/O delayed milestones

FINDINGS:

Diffuse bilateral periventricular, subcortical white matter T2, FLAIR hyperintense, T1 iso to hyperintense signal changes noted. Myelination of the posterior limb of the internal capsule, postero-lateral putamen, antero-lateral thalamus, brainstem, perirolandic white matter suggestive of delayed myelination.
Diffuse thinned out corpus callosum noted.
Benign enlargement of the bilateral frontal sub-arachnoid space noted (BESS)

CONCLUSION

Infantile Krabbe disease is a devastating neurodegenerative disorder with limited treatment options. Early recognition through neuroimaging, enzyme assays, and genetic testing is crucial for diagnosis and family counseling. HSCT has shown potential benefits if performed in pre-symptomatic infants, highlighting the importance of newborn screening in at-risk populations[4].

REFERENCES

[1] Wenger DA, Rafi MA, Luzi P. Krabbe disease: genetic aspects and progress toward therapy. Molecular Genetics and Metabolism, 2000;70(1):1-9.

[2] Escolar ML, Poe MD, Provenzale JM, et al. Transplantation of umbilical-cord blood in babies with infantile Krabbe's disease. New England Journal of Medicine, 2005;352(20):2069-2081.

[3] Duffner PK, Caviness VS, Erbe RW. The diagnosis and treatment of the infantile form of Krabbe disease: A clinical perspective. Journal of Child Neurology, 2009;24(3):268-273.

[4] Allewelt H, Taskindoust M, Troy J, et al. Long-term functional outcomes following hematopoietic stem cell transplantation for infantile Krabbe disease. Blood Advances, 2018;2(23):2656-2667.