

A Case Study: Bilateral Nephrolithiasis and Associated Pyelonephritis by Individualized Homoeopathic Medicine *Lycopodium Clavatum*

Dr. Mohammed Sadiq N. Mujawar¹, Dr. Yashwanth Reddy R²

¹Associate professor & HOD, Dept of Practice of medicine Shri Kamaxidevi HMC & H, Shiroda-Goa.403103

²Assistant professor, Dept of Physiology & Biochemistry Shri Kamaxidevi HMC & H, Shiroda-Goa.403103

Abstract—This case study details the successful homeopathic treatment of a 21-year-old female patient, who presented with bilateral renal calculi and an associated pyelonephritis. The patient experienced acute pain in the right lumbar region, a persistent burning sensation during urination. Initial diagnosis via ultrasound confirmed a 3.9mm stone in the right kidney and a 3.8mm stone in the left. Following a course of individualized homoeopathic remedy, *Lycopodium clavatum*. The patient reported a complete resolution of symptoms. Subsequent ultrasonography confirmed the absence of any calculi, and follow-up urine analysis showed the clearance of the associated bacterial infection. This case highlights the potential of homeopathic intervention as a viable treatment modality for small renal calculi and related urinary tract infections.

Index Terms—Bilateral renal calculi, nephrolithiasis, pyelonephritis, case study, individualisation, homoeopathy, *lycopodium clavatum*.

I. INTRODUCTION

Renal calculi, are hard deposits made of minerals and salts that form inside the kidneys. They can cause excruciating pain, known as renal colic, when they move into the ureter, the tube connecting the kidney and bladder. ⁽¹⁾ Often, renal stones are associated with urinary tract infections (UTIs). UTIs occur when bacteria enter the urinary tract, leading to symptoms like a burning sensation during urination (dysuria), frequent urination, and fever. If the infection ascends to the kidneys, it is termed pyelonephritis, a more serious condition that can cause fever, chills, and flank pain. ⁽²⁾ This case report examines the clinical journey

of a patient presenting with both small bilateral renal calculi and symptoms indicative of a UTI, who was managed successfully with Homeopathy.

Epidemiology

Nephrolithiasis is a common urological disorder affecting approximately 12% of the global population at some point in their lives. The prevalence has increased in recent decades due to dietary and lifestyle changes, with a higher incidence in men than women. ⁽³⁾

Urinary tract infections are among the most common bacterial infections worldwide, causing over 7 million physician visits annually and affecting about 150 million individuals each year. Women are significantly more affected than men. ⁽⁴⁾ In India, kidney stone disease affects around 12% of the population, and nearly half of these cases may result in kidney damage or renal failure. The so-called “stone belt” of India includes Maharashtra, Gujarat, Punjab, Haryana, Rajasthan, and Delhi, where the prevalence is particularly high. ⁽⁵⁾ UTIs are also highly prevalent in India, commonly seen in both community and hospital settings, especially among women. With the rise of antibiotic-resistant organisms, there is an urgent need for alternative approaches, including complementary systems like Homeopathy. ^(4,5)

Case Presentation

Patient Information:

- Name: Mrs. XYZ
- Age: 21 years
- Sex: Female
- Date of consultation: 26-03-2025

Chief Complaints

- Severe, colicky pain in the right flank radiating to the groin
- Burning micturition;
- For one month.

History of Chief Complaints

- Pain began one month prior, with increasing frequency.
- Episodes lasted 1–3 days, partially relieved by hydration and analgesics.
- Recent ultrasound confirmed a 3.9mm and 3.8mm calculus in both right and left kidneys respectively.
- Allopathy advised lithotripsy.

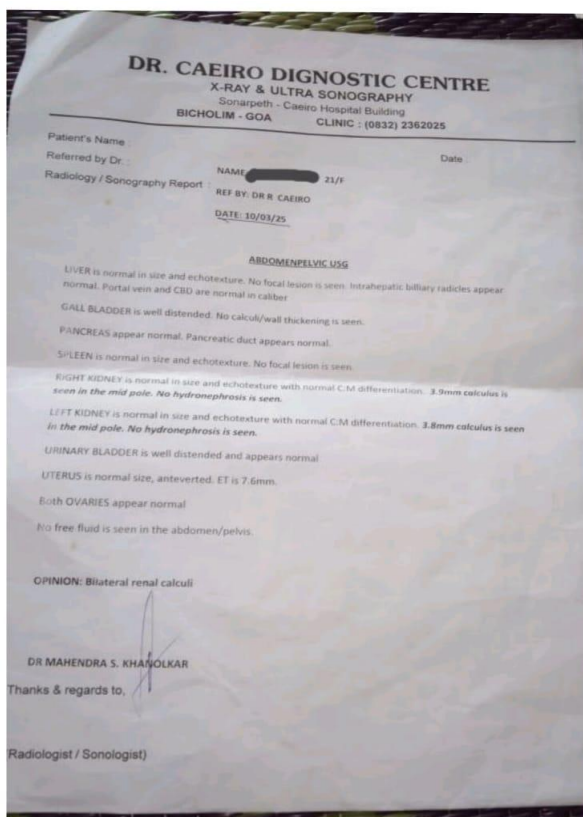
Generals & Mental Generals

- Appetite: Normal
- Thirst: Normal.
- Sleep: Disturbed during pain.
- Thermal state: Chilly patient.
- Desires: Sweets.
- Mind: Angered easily and violent, after anger many of his symptoms appear, Irritable, anxious about health, memory weak, afraid to be alone.

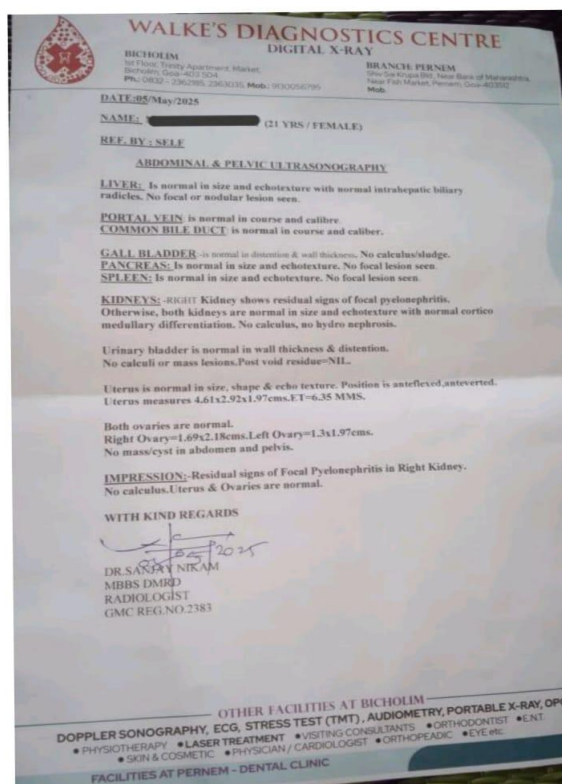
Clinical Examination

- Pulse: 82/min
- BP: 124/84 mmHg
- Abdomen: Grade 2 tenderness in right lumbar region
- No palpable mass

II. INVESTIGATION



Before Treatment



After Treatment

Totality of Symptoms

- Severe, colicky pain in the right flank radiating to the groin.

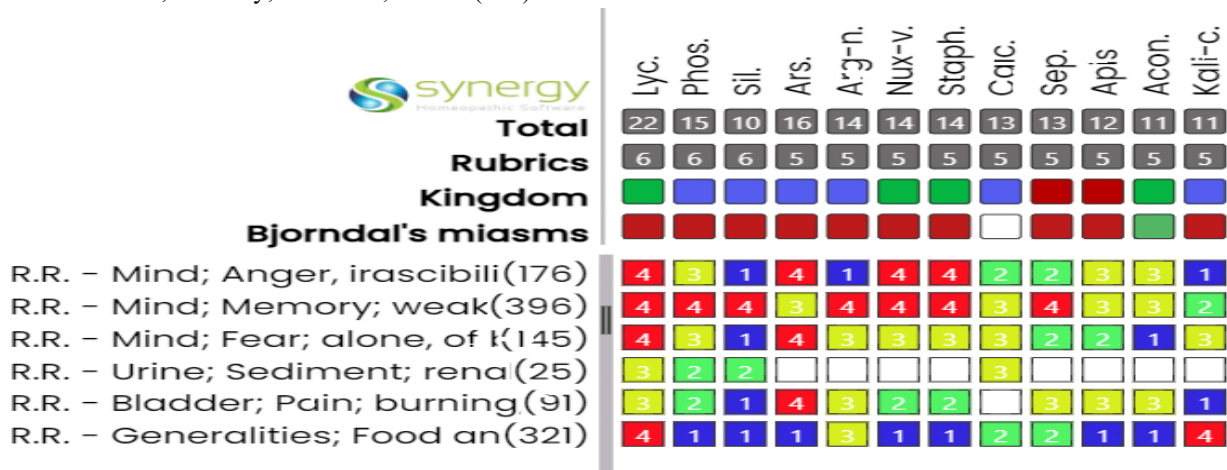
- Burning micturition;
- Desires: Sweets.
- Fear of being alone.

- Angered easily, after anger many of his symptoms appear.

Repertorial Analysis using Reliable Repertory using synergy homoeopathic software: ⁽⁸⁾

- R.R. - Mind; Anger, irascibility; ailments from (176)
- R.R. - Mind; Memory; weakness, loss of (396)

- R.R. - Mind; Fear; alone, of being (145)
- R.R. - Urine; Sediment; renal calculi (25)
- R.R. - Bladder; Pain; burning; urination; during (91)
- R.R. - Generalities; Food and drinks; sweets, dainties, delicacies; desire (321)



Remedy Selected:

Lycopodium Clavatum. 30CH BD 4 Days

Rationale for Remedy:

Lycopodium matched the renal complaint, personality traits, and modality of symptoms. Known affinity for renal systems ^(6,7)

Treatment plan:

Date	Symptoms	Prescription
26-03-2025	USG Abd was done on 10-03-2025 which revealed 3.9mm and 3.8mm calculi in right and left kidney respectively with pain in abdomen with burning micturition.	Lycopodium Clavatum 30 BD 4 days. Follow up after 2 weeks
Follow up date	Symptoms	Prescription
08-04-2025	Pain reduced in intensity. Burning urination is mildly present.	Placebo BD × 30 days Advised USG Abd and urine routine. Follow up after 1 month
08-05-2025	No Pain in abdomen. USG Abdomen was done on 05-05-2025 revealed No renal calculi but residual signs of pyelonephritis in right kidney. Mild burning during micturition. Urine routine was done on 06-05-2025 revealed presence of Bacteria	Placebo BD × 30 days Follow up after 1 month. Advised Urine Routine
09-06-2025	Urine Routine was done on 09-06-2025 revealed absence of bacteria	No medicines were prescribed, as the case is completely CURED.

Follow-up Urine Routine Report (Dated 09-06-2025):

- No Bacteria Present. No burning micturition.

- All abdominal organs normal
- Impression: Normal Study

BIO CARE
PATHOLOGY LABORATORY

Prasoti Pednekar
PDCCLMCLT
bio.carepathology@gmail.com
9527291065 / 9850093828

Gumeanti Centre, Near Bank of India, Opp. Shantadurga Medical Store, Bicholim.

Timing:
Weekdays: 8.30am - 6.30pm
Sunday: 8.30am - 12.00pm

Patient Name: [REDACTED]
Date: 06/05/2025
Age/Sex: 21 Years/ Female
Referred by: Dr. Mohammad

Parameters	Obs. Value	Ref. Range
URINE ANALYSIS:		
PHYSICAL EXAMINATION		
Sample	: Fasting	
Quantity	: 5ml	
Color	: Pale yellow	
Appearance	: CLEAR	
Reaction	: Acidic	
Specific Gravity	: 1.005	
Albumin	: Nil	
Glucose	: NIL	
MICROSCOPY		
Pus Cells	: OCCASIONAL	
RBC's	: ABSENT	
Epithelial Cells	: 1-2/HPF	
Casts	: Absent	
Crystals	: Absent	
Bacteria	: PRESENT+	

DR. P. PADMANABH
M.D. (D.C.P.) (PAC) (M.B.B.S.)
REG. NO. 2720 (GARC)
REG. NO. 7870 (HMMC)

Prasoti Priyal Pednekar
(Micro Biologist)
Clinical Genetics &
Medical Laboratory Technology
Bicholim - Goa.

2nd follow up

BIO CARE
PATHOLOGY LABORATORY

Prasoti Pednekar
PDCCLMCLT
bio.carepathology@gmail.com
9527291065 / 9850093828

Gumeanti Centre, Near Bank of India, Opp. Shantadurga Medical Store, Bicholim.

Timing:
Weekdays: 8.30am - 6.30pm
Sunday: 8.30am - 12.00pm

Patient Name: [REDACTED]
Date: 09/06/2025
Age/Sex: 21 Years/ Female
Referred by: C/o. Shri Kamaxidevi

Parameters	Obs. Value	Ref. Range
URINE ANALYSIS:		
PHYSICAL EXAMINATION		
Sample	: Fasting	
Quantity	: 5ml	
Color	: Pale yellow	
Appearance	: CLEAR	
Reaction	: Acidic	
Specific Gravity	: 1.010	
Albumin	: Nil	
Glucose	: NIL	
MICROSCOPY		
Pus Cells	: OCCASIONAL	
RBC's	: ABSENT	
Epithelial Cells	: 1-2/HPF	
Casts	: Absent	
Crystals	: Absent	
Bacteria	: Absent	

DR. P. PADMANABH
M.D. (D.C.P.) (PAC) (M.B.B.S.)
REG. NO. 2720 (GARC)
REG. NO. 7870 (HMMC)

Prasoti Priyal Pednekar
(Micro Biologist)
Clinical Genetics &
Medical Laboratory Technology
Bicholim - Goa.

3rd follow up

III. DISCUSSION

The case demonstrates the efficacy of classical Homoeopathy in renal calculi, particularly where *Lycopodium* is indicated. *Lycopodium* acts on the urinary tract, supports spontaneous stone passage, and improves general vitality ^(6,7). The patient who had bilateral renal calculi of size 3.9mm in right and 3.8mm in left, after two follow ups came up with the report revealing no renal calculi and mild focal pyelonephritis in right kidney which was again an indication of *lycopodium*. Urine routine shows presence of bacteria. After a month urine routine was repeated which revealed absence of bacteria. Modern studies also highlight the scope of individualized Homoeopathy in chronic conditions ^(2,3).

IV CONCLUSION

This case illustrates the potential efficacy of individualized homeopathic treatment in managing small bilateral renal calculi and focal pyelonephritis. Objective evidence through ultrasonography and urine analysis supports the complete resolution of both the

stones and the infection. Homeopathy offers a promising, non-invasive alternative for selected cases of nephrolithiasis and UTIs, warranting broader clinical research in integrative and evidence-based contexts.

REFERENCES

- [1] Mayo Clinic. Kidney stones - Symptoms and causes [Internet]. [cited 2025 Jul 23]. <https://www.mayoclinic.org/diseases-conditions/kidney-stones/symptoms-causes/syc-20355755>
- [2] Centres for Disease Control and Prevention. Urinary Tract Infection [Internet]. [cited 2025 Jul 23]. <https://www.cdc.gov/antibiotic-use/uti.html>
- [3] Khan SR, Pearle MS, Robertson WG, Gambaro G, Canales BK, Doizi S, et al. Kidney stones. *Nat Rev Dis Primers*. 2016; 2:16008.
- [4] Medina M, Castillo-Pino E. An introduction to the epidemiology and burden of urinary tract infections. *Ther Adv Urol*. 2019; 11:1756287219832172.

- [5] Reddy PP, Kumar SMP, Nagireddy MRDD. The prevalence of urolithiasis in India. *Int J Res Med Sci.* 2018;6(1):294.
- [6] Boericke W. *Pocket Manual of Homoeopathic Materia Medica and Repertory.* 9th ed. New Delhi: B. Jain Publishers; 1927.
- [7] Clarke JH. *A Dictionary of Practical Materia Medica.* Vol. 1–3. New Delhi: B. Jain Publishers; 1900.
- [8] Synergy Homoeopathic Software – 1.5-5CL-ENG D.1.5 (1025).