

Effect Of Jalukavcharan in The Management of Puyalasa (Acute Dacryocystitis)

Dr. Sivakumar Dande

Professor, Department of Shalakyta Tantra, SGT University, Gurugram Haryana

Abstract— Background: Puyalasa is described in classical Ayurvedic texts as a suppurative inflammatory condition occurring at the inner canthus of the eye, characterized by swelling, pain, and purulent discharge. It can be clinically correlated with Acute Dacryocystitis, a persistent infection of the lacrimal sac commonly resulting from nasolacrimal duct obstruction. Conventional management primarily includes antibiotics and surgical intervention; however, recurrence and post-surgical complications remain concerns. In Ayurveda, localized inflammatory conditions involving vitiation of Pitta and Rakta are effectively managed through Raktamokshana, particularly Jalaukavacharana. **Objective** To evaluate the clinical efficacy of Jalaukavacharana in the management of Pualasa (Acute Dacryocystitis). **Case Presentation** A 26-year-old female presented with complaints of epiphora, mucopurulent discharge, tenderness, and swelling over the lacrimal sac region for six months. Based on clinical findings and Ayurvedic assessment, the condition was diagnosed as Puyalasa. **Intervention** Jalaukavacharana was performed locally over the lacrimal sac region in three sittings at weekly intervals, following proper procedural guidelines of Raktamokshana. **Results** Significant improvement was observed in swelling, tenderness, and purulent discharge. Lacrimal sac regurgitation reduced markedly, indicating improved drainage and reduction of local inflammation. **Conclusion** The study suggests that Jalaukavacharana may serve as a safe and minimally invasive therapeutic option in the management of Puyalasa. Its anti-inflammatory and microcirculatory enhancing effects may contribute to clinical improvement. Further large-scale studies are warranted to substantiate these findings.

Index Terms— Jalaukavacharana, Puyalasa, Raktamokshana, Acute Dacryocystitis, Nasolacrimal Duct Obstruction

I. INTRODUCTION

Puyalasa is described in classical Ayurvedic ophthalmology under Sandhigata Netraroga, presenting with localized swelling, pain, and suppuration at the inner canthus of the eye. The term itself denotes accumulation of pus (puya) in the lacrimal region, indicating an inflammatory pathology predominated by vitiation of Pitta and Rakta. Classical texts describe features such as shophya (swelling), toda (pricking pain), and srava (discharge), which closely resemble infective conditions of the lacrimal sac. ¹in contemporary ophthalmology, Acute Dacryocystitis refers to persistent inflammation of the lacrimal sac caused primarily by nasolacrimal duct obstruction, leading to stagnation of tears and secondary bacterial infection. Patients typically present with epiphora, mucopurulent discharge, regurgitation on pressure over the lacrimal sac, and recurrent conjunctival congestion. ² Although antibiotics provide temporary relief, definitive management often requires surgical procedures such as dacryocystorhinostomy (DCR). However, surgical interventions may be associated with recurrence, scarring, bleeding, and procedural morbidity. ³According to Ayurvedic principles, diseases involving localized inflammation, discoloration, burning sensation, and suppuration are commonly associated with vitiated Pitta and Rakta. Raktamokshana is advocated as an effective therapeutic measure in such conditions, particularly when pathology is confined to a localized area. Among various methods of Raktamokshana, Jalaukavacharana (leech therapy) is considered gentle (mridu) and specifically indicated in delicate and sensitive regions including the ocular area. Leech saliva contains bioactive substances such as hirudin, calin, destabilase, and hyaluronidase, which exhibit anti-inflammatory, anticoagulant, analgesic, and

microcirculatory enhancing properties. Modern studies have demonstrated its efficacy in inflammatory and congestive conditions by improving local blood flow and reducing edema. ⁵ These pharmacological actions provide a plausible scientific rationale for the use of Jalaukavacharana in conditions like Acute Dacryocystitis correlated with Puyalasa. Considering the limitations of conventional management and the classical indication of Jalaukavacharana in localized inflammatory disorders, the present case report aims to evaluate its therapeutic effect in a clinically diagnosed case of Acute Dacryocystitis (Puyalasa). ⁶

II. CASE PRESENTATION

1. Patient Information

Parameter	Details
Age	26 years
Gender	Female
Occupation	Homemaker
OPD No.	2026/OPD/117
Date of First Visit	12 January 2026

2. Chief Complaints

Complaint	Duration
Watering from left eye (Epiphora)	6 months
Swelling near inner canthus	5 months
Mucopurulent discharge	4 months
Mild pain & tenderness	4 months

3. History of Present Illness

The patient was apparently well six months back when she gradually developed excessive watering from the Right eye. This was followed by swelling over the lacrimal sac region and intermittent mucopurulent discharge. Symptoms aggravated on exposure to dust and cold weather. Local antibiotics provided temporary relief, but recurrence was noted. There was no history of trauma, previous nasal surgery, or systemic illness like diabetes or tuberculosis.

4. Past History

- No history of major systemic illness
- No history of previous ophthalmic surgery
- No known drug allergy

5. Personal History

Parameter	Status
Appetite	Normal
Bowel	Regular

Sleep	Disturbed due to watering
Addiction	None

6. General Examination

Parameter	Findings
Pulse	78/min
BP	122/80 mmHg
Temperature	Afebrile
Pallor/Icterus	Absent

7. Local Ophthalmic Examination

Finding	Observation
Swelling	Present over Right lacrimal sac
Tenderness	Mild positive
Regurgitation Test	Positive (mucopurulent discharge)
Conjunctiva	Mild congestion

These findings were suggestive of Acute Dacryocystitis.

8. Ayurvedic Assessment

Based on classical features, the condition was diagnosed as Puyalasa, characterized by involvement of vitiated Pitta and Rakta localized in Netra Sandhi. The presence of suppuration (puya), swelling (shopha), and discharge (srava) indicated Rakta dushti with localized inflammatory pathology.

9. Diagnosis

- Modern Diagnosis: Acute Dacryocystitis (Right Eye)
- Ayurvedic Diagnosis: Puyalasa

III. INTERVENTION

- Treatment Plan
- Considering the localized inflammatory pathology and involvement of vitiated Pitta and Rakta, Jalaukavacharana was planned as the primary line of management.

Intervention	Plan
Procedure	Jalaukavacharana
Site	Right lacrimal sac region (inner canthus)
Number of sittings	3 sittings
Interval	7 days between sittings
Follow-up	Weekly for 1 month

IV. PROCEDURE OF JALAUKAVACHARANA

- The procedure was performed under strict aseptic precautions and divided into three stages:
 - 1. Purva Karma (Pre-operative Procedure)

Step	Description
Patient Preparation	Explained procedure and obtained written consent
Local Cleaning	Area cleaned with sterile normal saline
Selection of Leech	Medium-sized, healthy leech selected
Site Preparation	Gentle rubbing to stimulate local circulation

- 2. Pradhana Karma (Main Procedure)

Step	Description
Application	Leech applied over maximum swelling point
Attachment Time	20–30 minutes (until spontaneous detachment)
Monitoring	Continuous observation for discomfort or excessive bleeding
Detachment	Allowed natural detachment; no forced removal

- The leech was removed once it showed signs of complete sucking (inactivity and spontaneous release). Mild oozing of blood was allowed to continue for a few minutes to ensure adequate localized bloodletting.

- 3. Paschat Karma (Post-operative Care)

Step	Description
Wound Care	Sterile dressing applied
Bleeding Control	Mild pressure dressing
Observation	Monitored for 30 minutes
Advice	Avoid rubbing eye, exposure to dust, and cold wind

V. PATHYA – APATHYA

Pathya	Apathya
Light, easily digestible diet	Spicy and fermented food
Warm water intake	Excessively oily food
Adequate sleep	Late-night awakening
Eye hygiene maintenance	Dust exposure

VI. TREATMENT TIMELINE

Sitting	Date	Clinical Observation
1st Sitting	Day 1	Marked reduction in tension & mild decrease in swelling
2nd Sitting	Day 7	Significant reduction in discharge
3rd Sitting	Day 14	Swelling minimal, regurgitation markedly reduced

VII. ASSESSMENT CRITERIA

Clinical assessment was done using both subjective and objective parameters before the first sitting and after completion of three sittings of Jalaukavacharana.

1. Subjective Parameters

Grading of Pain

Grade	Description
0	No pain
1	Mild pain (tolerable, no medication required)
2	Moderate pain (disturbs routine activity)
3	Severe pain (requires medication)

Grading of Epiphora

Grade	Description
0	No watering
1	Occasional watering
2	Frequent watering
3	Constant watering

2. Objective Parameters

Grading of Swelling (Lacrimal Sac Region)

Grade	Clinical Finding
0	No swelling
1	Mild visible swelling
2	Moderate swelling
3	Marked tense swelling

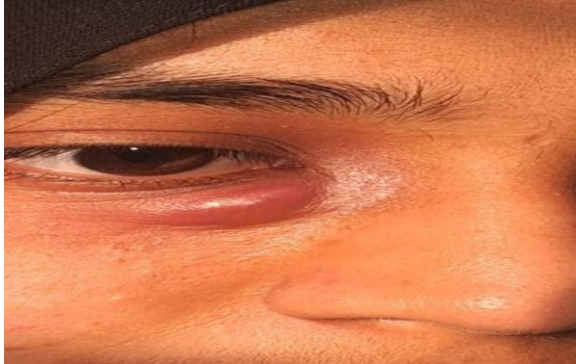Regurgitation on Pressure Test

Grade	Observation
0	No regurgitation
1	Serous fluid regurgitation
2	Mucopurulent discharge
3	Frank purulent discharge

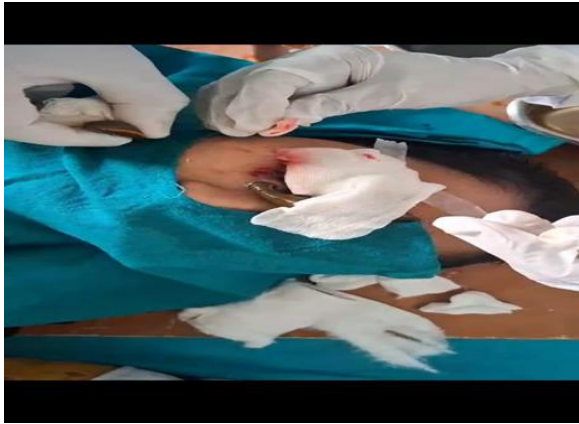
VIII. RESULTS

Before and After Comparison


Parameter	Before Treatment	After 3rd Sitting	% Improvement
Pain	Grade 2	Grade 0	100%
Epiphora	Grade 3	Grade 1	66%
Swelling	Grade 3	Grade 0	100%
Regurgitation	Grade 3	Grade 1	66%



Before Treatment



During Treatment



After Treatment

There was marked clinical improvement in all parameters after three sittings of Jalaukavacharana. Swelling subsided completely and regurgitation decreased significantly. No adverse reactions were observed during or after the procedure.

REFERENCES

- [1] Vagbhatta, Ashtanga Hridaya (Uttara Sthana), with Sarvang Sundara commentary, K. R. Srikantha Murthy, Trans. Varanasi, India: Chaukhambha Krishnadas Academy, 2012.
- [2] American Academy of Ophthalmology, Basic and Clinical Science Course: External Disease and Cornea. San Francisco, CA, USA: AAO Press, 2021.
- [3] M. J. Ali, "Dacryocystorhinostomy: Current concepts and controversies," Saudi Journal of Ophthalmology, vol. 29, no. 4, pp. 251–256, 2015.
- [4] Sushruta, Sushruta Samhita (Sutra Sthana), with English translation, P. V. Sharma, Trans. Varanasi, India: Chaukhambha Vishvabharati, 2014.
- [5] S. Whitaker, J. Rao, and D. Izadi, "Historical article: Hirudo medicinalis—ancient origins of, and trends in, the use of medicinal leeches throughout history," British Journal of Oral and Maxillofacial Surgery, vol. 42, no. 2, pp. 133–137, 2004.
- [6] Gupta and S. Singh, "Leech therapy: A holistic approach of treatment in Ayurveda," International Research Journal of Pharmacy, vol. 2, no. 4, pp. 31–33, 2011.