

Role of Apamarga Kshara in Reducing Recurrence of Mucocele Post-Surgery: An Evidence-Based Case Study

Dr. Vidya Patil¹, Dr. Pallavi Ambore,² Dr. Rajendra Dhate³

¹PG Scholar, Department of Shalakyatantra, R.A.P.M.C., Worli, Mumbai, Maharashtra, India.

²PG Scholar, Department of Shalakyatantra, R.A.P.M.C., Worli, Mumbai, Maharashtra, India

³Professor & HOD, Department of Shalakyatantra, R.A.P.M.C., Worli, Mumbai, Maharashtra, India.

Abstract—

Background: Mucocele is the most common benign cystic lesion of the oral mucosa, arising primarily from minor salivary gland ducts. Despite surgical excision being the standard treatment, recurrence rates remain notably high, particularly in young adults. In Ayurveda, oral mucocele correlates with Vata Kaphaja Osthā Jalarbuda. Apamarga Kshara (alkaline caustic derived from *Achyranthes aspera*) exerts Shodhana (purification) and Lekhana (scraping) properties, offering a rational pharmacological basis for preventing post-surgical recurrence.

Case Presentation: A 28-year-old male engineer from Pune, Maharashtra, presented to the OPD on 28 April 2025 with a one-month history of painless progressive swelling on the inner aspect of the lower lip, accompanied by mild discomfort during eating and speaking. The patient had a documented prior episode of mucocele managed with allopathic medication and surgical excision approximately four months earlier, following which recurrence occurred. Surgical excision of the mucocele was performed under local anaesthesia (2% lignocaine), followed immediately by application of Pratisaraneeya Apamarga Kshara to the surgical bed. The Kshara was neutralised after Shatmatra Kala (100 seconds) using Nimbu Swarasa (lemon juice). Post-operative follow-up was conducted at Day 3, Day 7, Day 14, and at 3 months.

Results: The lesion demonstrated progressive healing with normalisation of mucosal colour by Day 7. At 3-month follow-up, no recurrence was detected, and no visible scarring was present, indicating excellent cosmetic and clinical outcome.

Conclusion: Adjuvant post-surgical application of Apamarga Kshara significantly reduces mucocele recurrence by ablating residual mucin-secreting epithelium through its Ksharana, Lekhana, and Shodhana properties. This integrative approach offers a safe, minimally invasive, and cosmetically superior alternative to repeat surgical excision.

Keywords— Apamarga Kshara, Mucocele, Kshara Karma, Jalarbuda, Pratisaraneeya Kshara,

Recurrence, Shalakyatantra, Oral Mucocele, Post-surgical management.

I. INTRODUCTION

Mucocele, also referred to as a mucous retention or extravasation cyst, represents the most frequently encountered benign soft-tissue lesion of the oral cavity. It originates from minor salivary glands or their ductal apparatus and is classified into two principal subtypes: extravasation mucocele, which accounts for over 80% of all cases, arising secondary to traumatic ductal rupture (typically from habitual lip-biting), and the comparatively rare retention mucocele, resulting from ductal obstruction.¹⁴

Clinically, mucoceles manifest as smooth, painless, dome-shaped fluctuant swellings with a translucent bluish hue, ranging in size from a few millimetres to 2 centimetres or larger for deeper lesions. They most commonly arise on the inner aspect of the lower lip, particularly at the bicuspid level, and may also appear on the buccal mucosa, floor of the mouth, palate, and tongue. The population-level incidence is estimated at 0.4–0.9%, with no significant sex predilection. The condition is predominantly observed in younger individuals and is associated with a well-recognized propensity for post-excision recurrence.¹⁴

Conventional management of mucocele includes surgical excision, marsupialization, laser ablation, cryotherapy, and micro marsupialization. Of these, surgical excision remains the most widely practiced approach. However, incomplete removal of the associated minor salivary gland or its ductal remnants frequently leads to recurrence, necessitating repeat interventions that are both clinically and cosmetically suboptimal. This persistent recurrence challenge necessitates an

adjunctive therapeutic strategy capable of destroying residual pathological tissue at the surgical base.¹⁴

In the classical Ayurvedic framework of Shalakyatantra, oral mucocele aligns most closely with Vata Kaphaja Osthā

Jalarbuda — a Kapha and Vata-predominant cystic condition of the lip characterised by fluid accumulation and mucoid secretion. Kshara Karma, the para-surgical alkaline cauterisation technique, is described in foundational Ayurvedic texts including the Sushruta Samhita as a superior therapeutic instrument (Anushastra) capable of simultaneously achieving Chedana (excision), Bhedana (incision), and Lekhana (scraping). Among the various Kshara formulations, Apamarga Kshara — prepared from the alkaline ash extract of *Achyranthes aspera* — has demonstrated broad applicability across surgical, para-surgical, and wound-healing contexts.^{1,13}

The Pratisaraneeya (externally applied) form of Apamarga Kshara possesses specific pharmacological actions including Dahana (cauterisation), Vilayana (tissue dissolution), Shoshana (desiccation), Shodhana (wound purification), and Ropana (tissue healing). These properties make it a scientifically and theoretically sound adjunct to conventional mucocele surgery in eliminating the residual mucin-secreting epithelium responsible for recurrence. The present evidence-based case study documents the clinical outcome of post-surgical Apamarga Kshara application in a patient with documented mucocele recurrence following prior conventional surgery.^{1,8}

II. AIM AND OBJECTIVES

2.1 Aim

To assess the therapeutic role of Apamarga Kshara, applied post-surgically, in preventing the recurrence of lower lip mucocele.

2.2 Objectives

To evaluate the combined clinical outcome of surgical excision followed by Pratisaraneeya Apamarga Kshara application.

To assess the recurrence rate at structured follow-up intervals (Day 3, Day 7, Day 14, and 3 months). To document wound healing progression, cosmetic outcomes, and patient-reported discomfort.

To elucidate the pharmacological mechanism by which Apamarga Kshara reduces mucocele recurrence within the Ayurvedic and biomedical frameworks.

III. CASE REPORT

3.1 Patient Demographics

Parameter	Details
Name	XYZ (identity concealed)
Registration No.	38722
Age	28 years
Gender	Male
Nationality	Indian
State / District	Maharashtra / Pune
Occupation	Engineer
Date of Presentation	28 April 2025

3.2 Chief Complaints

Painless, progressively enlarging swelling on the inner aspect of the lower lip — duration 1 month. Progressive increase in swelling size over the preceding 2 weeks.

Mild discomfort during eating and speaking — duration 2 weeks.

3.3 History

Past History: The patient presented with a documented history of lower lip mucocele approximately 4 months prior to the current episode (December 2024). At that time, he had undergone conventional allopathic treatment including pharmacological management and surgical excision. Despite initial resolution, mucocele recurrence was noted within 4 months, prompting the patient to seek Ayurvedic management at our OPD.

Personal History: The patient is a working engineer by profession. No significant dietary abnormalities were noted. He denied any lip-biting habit at the time of current presentation.

Family History: All family members reported to be in good health. No familial history of similar oral lesions.

Drug History: Tab. Vitamin supplement 1 OD for 3 months (prescribed post prior surgery).

Addiction History: No known addiction. No history of tobacco use or alcohol.

Allergy History: No known drug or food allergies. No prior anaphylactic episodes.

3.4 Clinical Examination

On Oral Examination: A round, pale, soft, fluctuant swelling was identified on the inner aspect of the lower lip toward the lateral side, measuring approximately 3 mm in diameter. The swelling was smooth-surfaced, non-tender on palpation, and contained translucent mucoid fluid. The surrounding mucosa appeared normal with no associated ulceration, erythema, or lymphadenopathy.

Ayurvedic Assessment: The clinical presentation was consistent with Vata Kaphaja Otha Jalarbuda Kapha-predominant cystic accumulation at the lip region with Vata-mediated pain tendency. The Kaphaja nature was evidenced by the mucoid, translucent, and smooth characteristics of the swelling.

IV. MATERIAL AND METHODS

4.1 Drug Used: Apamarga Kshara (Pratisaraneeya)
Apamarga Kshara is the alkaline preparation derived

from the whole plant ash extract of *Achyranthes aspera* Linn. (Family: Amaranthaceae). It is classified as Pratisaraneeya Kshara — intended for direct external topical application. The preparation process involves incineration of dried plant material, dissolution of ash in water (at a ratio of 1:6), filtration through 21 layers of cloth, and subsequent evaporation to yield a concentrated white alkaline powder. The resultant Kshara is dominated by potassium and sodium carbonates/hydroxides, which confer its alkaline (pH >10) and caustic properties.^{6,11}

4.2 Pharmacological Properties of Apamarga Kshara

Ayurvedic Property	Sanskrit Term	Therapeutic Significance
Cauterisation	Dahana	Destroys residual pathological tissue
Tissue Dissolution	Vilayana / Lekhana	Sloughs off remnant mucin-secreting cells
Desiccation	Shoshana	Removes excessive fluid from surgical bed
Wound Purification	Shodhana	Prevents infection and promotes sterile healing
Tissue Healing	Ropana	Stimulates healthy granulation and mucosal regeneration
Suppuration	Pachana	Resolves residual inflammatory material

4.3 Treatment Protocol

Step 1 — Shastra Karma (Surgical Excision): Surgical excision of the mucocele was performed under local anaesthesia using 2% lignocaine with adrenaline (1:80,000). The cystic lesion was excised en bloc with careful dissection to preserve surrounding mucosa. The associated minor salivary gland lobule was identified and removed along with the specimen to reduce standard surgical recurrence risk.

Step 2 — Kshara Karma (Pratisaraneeya Apamarga Kshara Application): Immediately following surgical excision and haemostasis, Pratisaraneeya Apamarga Kshara was applied uniformly over the surgical wound bed using a sterile spatula. The Kshara was left in contact with the tissue for Shatmatra Kala (one hundred seconds,

approximately 100 seconds as per classical enumeration). The Kshara was then neutralised and removed by thorough irrigation with Nimbu Swarasa (fresh lemon juice — *Citrus limon*), which reduces the alkalinity and halts further caustic action through acidic neutralisation. The Kshara application serves to ablate any residual mucin-secreting ductal epithelium remaining after surgical excision, which is the primary substrate for recurrence.^{1,10}

Step 3 — Pathya-Apathya (Dietary and Lifestyle Instructions): The patient was instructed to avoid lip-biting behaviour, hard or mechanically irritating food, excessively spicy food items, and unnecessary excessive talking during the healing period to prevent mucosal trauma and secondary infection.

4.4 Follow-Up Schedule

Follow-Up Visit	Date	Observations
Post-Op Day 1	30 Apr 2025	Wound bed visible; mild post-operative oedema; Kshara action zone demarcated
Post-Op Day 3	01 May 2025	Reduction in oedema; early epithelialisation initiated at wound margins

Post-Op Day 7	07 May 2025	Lesion significantly reduced; mucosal colour normalised to match surrounding tissue; no discharge
Post-Op Day 14	12 May 2025	Complete wound closure; smooth mucosal surface; no induration or residual swelling
3-Month Follow-Up	07 Aug 2025	No recurrence; no visible scar; normal mucosal appearance; patient asymptomatic

V.RESULTS

The clinical outcome following the combined intervention of surgical excision and post-operative Pratisaraneeya Apamarga Kshara application was evaluated across all follow-up visits. The principal findings are summarised as follows:⁴

Wound healing progressed rapidly and without complication. By Day 7, the surgical site demonstrated near-complete epithelialisation with normalisation of mucosal colour and texture, comparable to the surrounding healthy mucosa. No signs of infection, excessive inflammation, or dehiscence were noted at any follow-up visit. Patient-reported discomfort was minimal and limited to mild

transient burning sensation at the time of Kshara application, which resolved immediately upon neutralisation with Nimbu Swarasa.

At the 3-month follow-up assessment (07 August 2025), the mucosal surface was completely restored with no evidence of cyst recurrence, palpable swelling, or fluid accumulation.

Cosmetic outcome was excellent — no visible scar formation was observed, consistent with the expected Ropana (healing-promoting) action of Apamarga Kshara on mucosal tissue.

Patient satisfaction was high, with full restoration of oral comfort during eating and speaking. The patient reported no difficulty or awareness of the previously treated site.

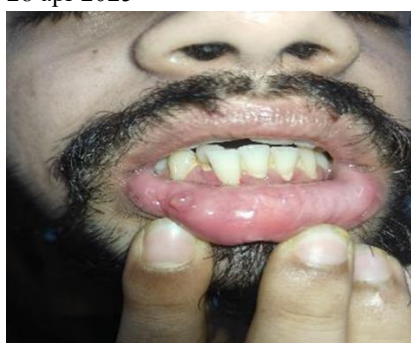Comparison of pre-treatment and post-treatment status:

Parameter	Pre-Treatment	Post-Treatment (3 months)
Swelling	Round, pale, 3 mm, fluctuant	Absent — complete resolution
Discomfort	Present (eating & speaking)	Absent
Recurrence	Prior episode 4 months ago	No recurrence at 3 months
Mucosal Colour	Pale bluish translucent cyst	Normal, uniform mucosal colour
Scar	N/A	No visible scarring
Patient Comfort	Mildly impaired	Fully restored

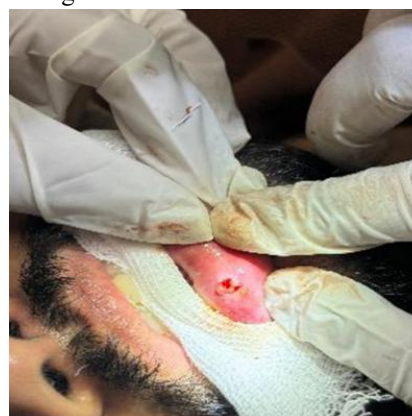
BEFORE AND AFTER ASSESSEMENT

1) On oral examination A round ,pale softy swelling was seen over inner aspect of lower lip towaerd lateral side .the mucocele was around 3mm in diameter.

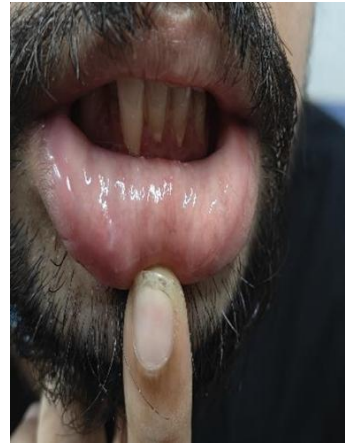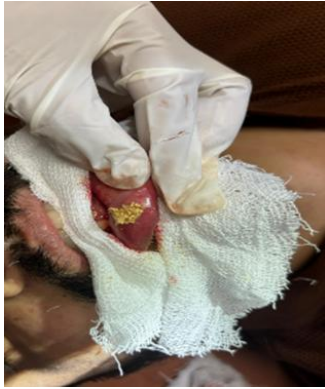Date 28 apr 2025



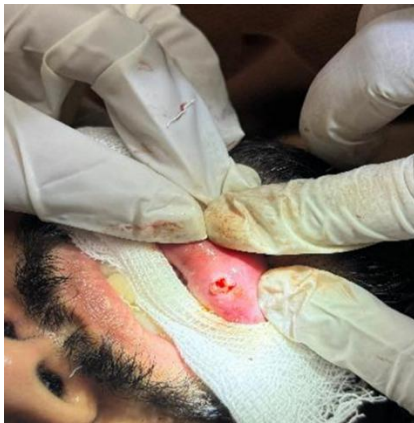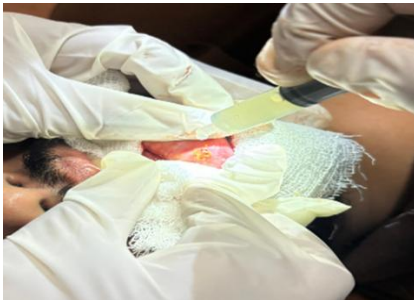
2) After surgical excision of mucocele



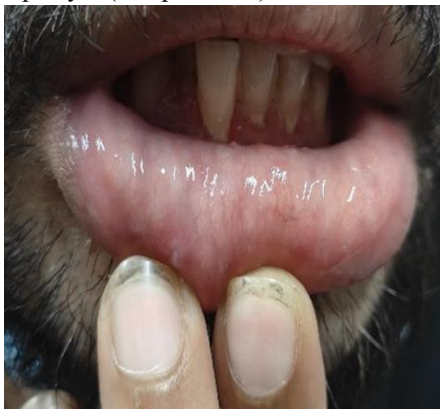3) Application of apamarga kshar



4) Nimbu swaras cleaning.



Post Op day 1 (30 april 2025)



After 7 th day lesion gradually reduced and colour had Also attained normal as surrounding mucosa (7 may 2025)

On follow up after 3 month showed no recurrence, no visible scar (7 august 2025)

VI.DISCUSSION

The recurrence of mucocele following conventional surgical excision is a recognised clinical challenge, with published recurrence rates varying from 3% to over 30% depending on surgical technique, patient compliance, and the completeness of glandular tissue removal. The primary pathophysiological substrate for recurrence is the persistence of functional mucin-secreting minor salivary gland tissue or ductal epithelium at the excision margin. Standard surgical excision, while effective in removing the bulk of the lesion, does not reliably guarantee complete ablation of these residual tissue elements, particularly in deeper extravasation-type lesions.¹⁴

The present case, involving a patient with confirmed recurrence within four months of prior surgical excision, represents a clinically important scenario in which adjunctive tissue ablation at the surgical bed is both justified and necessary. Pratisaraneeya Kshara Karma was selected as the adjunctive modality based on sound Ayurvedic diagnostic and therapeutic principles. The Kshara Yogya assessment confirmed the patient's suitability for Kshara application, given the chronicity of the condition, documented recurrence tendency, and the mucosal nature of the lesion.

The mechanism by which Apamarga Kshara prevents mucocele recurrence can be understood through both Ayurvedic pharmacodynamics and contemporary biomedical interpretation. The Teekshna (sharp/penetrating) and Ushna (hot) properties of Kshara enable it to penetrate deeply into the residual tissue at the wound bed, exceeding the depth achieved by the surgeon's blade alone. The Ksharana (alkaline dissolution) and Kshananata (tissue ablation) properties, as elaborated by

Dalhanacharya in the commentary to Sushruta Samhita, produce a chemical cauterisation of residual mucin-secreting epithelium, eliminating the anatomical substrate for recurrence. This action is functionally analogous to the chemical cauterisation achieved with trichloroacetic acid (TCA) in modern wound management but is derived from a natural herbal source with additional Shodhana (purification) and Ropana (healing) properties that benefit post-operative wound biology.^{1, 10, 11}

The Shodhana property of Apamarga Kshara confers antimicrobial and anti-inflammatory effects at the wound site, reducing the risk of post-operative infection and promoting a clean, sterile wound bed conducive to organised healing. The Ropana action subsequently promotes healthy granulation tissue formation and mucosal regeneration, explaining the absence of scar formation observed at the 3-month follow-up. The alkaline pH generated by Kshara at the wound surface also creates an unfavourable local environment for re-establishment of secretory ductal epithelium.^{6, 8}

The use of Nimbu Swarasa (lemon juice) for neutralisation following Shatmatra Kala (100 seconds) is a classical Paschat Karma that limits the depth of Kshara penetration, preventing inadvertent deep tissue damage while ensuring sufficient contact time for therapeutic effect. This represents an elegant, clinically controllable approach to chemical cauterisation that avoids the risk of excess tissue

destruction associated with uncontrolled alkaline exposure.^{1, 12}

Comparison with existing literature further supports the therapeutic rationale of this intervention. Raju et al. (2022)⁴ documented the successful application of Apamarga Kshara in ENT conditions including mucocele (Jalarbuda) with no recurrence at follow-up after three sessions. Tiwari et al. (2021) reported successful Kshara Karma management of umbilical granuloma, demonstrating its applicability across diverse soft-tissue lesions. The present case extends this evidence base to post-surgical oral mucocele management, demonstrating that a single intraoperative Kshara application suffices to prevent recurrence when combined with surgical excision.

From a patient-centred perspective, the combined approach demonstrated superior outcomes compared to the patient's prior surgical-only management: not only was recurrence prevented, but the healing was aesthetically excellent with no scarring, minimal post-procedural discomfort, and rapid mucosal restoration. These outcomes reflect the distinctive advantage of integrating classical Ayurvedic para-surgical techniques into contemporary oral surgical practice.^{4, 5}

VII. PROPOSED MECHANISM OF ACTION

The stepwise mechanism by which Pratisaraneeya Apamarga Kshara prevents mucocele recurrence is summarised in the following sequential pathway:

Stage	Mechanism / Effect
1. Post-Surgical Application	Kshara applied uniformly to exposed surgical wound bed of lower lip mucocele
2. Teekshna + Ushna Properties	Deep penetration into residual mucin-secreting epithelial tissue beyond surgical margin
3. Ksharana + Lekhana	Alkaline chemical ablation and scraping-off of remnant mucous gland tissue and ductal epithelium
4. Shodhana	Wound purification, antimicrobial action, and clearance of pathogenic Kapha accumulation
5. Ropana	Promotion of healthy granulation tissue, mucosal regeneration, and collagen remodelling
6. Outcome	Reduced recurrence risk + excellent cosmetic healing + no scarring

VIII. CONCLUSION

This evidence-based case study demonstrates that adjuvant post-surgical application of Pratisaraneeya Apamarga Kshara constitutes a highly effective, safe, and clinically rational strategy for preventing mucocele recurrence following surgical excision.

Surgical excision alone, while the contemporary standard of care, carries a well-documented recurrence risk attributable to residual mucin-secreting tissue. The application of Apamarga Kshara to the surgical wound bed for a controlled Shatmatra Kala chemically ablates this residual tissue through its combined Ksharana, Lekhana,

Shodhana, and Ropana pharmacodynamics, eliminating the anatomical substrate for recurrence.³ The present case achieved complete clinical resolution without recurrence at 3-month follow-up, with no visible scar, excellent mucosal healing, and high patient satisfaction. The absence of significant complications and the minimal post-procedural discomfort further establish the safety and patient acceptability of this integrative approach. The cosmetically superior outcome — characterised by natural mucosal surface restoration without fibrotic scarring— reflects an inherent advantage of Kshara Karma over repeated conventional surgical interventions.

Apamarga Kshara, within its Ayurvedic pharmacological framework, effectively fulfils the criteria of an Anushastra capable of achieving Chedana, Bhedana, and Lekhana simultaneously — properties uniquely suited to addressing the mucosal tissue pathology underlying mucocele recurrence. This case thus provides preliminary clinical evidence supporting the systematic integration of Kshara Karma into established oral surgical protocols for mucocele management, particularly in patients with a history of prior recurrence. Larger prospective clinical trials are warranted to establish standardised protocols and generate robust evidence for wider clinical adoption.^{1,2}

REFERENCES

- [1] Susruta M. Susruta Samhita (Ed. Ambika Dutta Shastri). Chaukhambha Sanskrit Sansthan, Varanasi, 2006; Vol. 2: 39–41.
- [2] Sharma PV. Charaka Samhita of Agnivesha, Chikitsa Sthana, Ch. 15, Ver. 178 (Reprint). Chaukhamba Orientalia, Varanasi, 2011: 299.
- [3] Thomson RJ, Padmakumaran Nair KG, Pillai JS. A Review of the Applications of Kshara Karma in Ayurveda. *Int. J. Res. Ayurveda Pharm.* 2023; 14(4): 77–82. DOI: 10.7897/2277-4343.1404118.
- [4] Raju S. Kshara Karma in diseases of Shalaky Tantra — Case Series. *Journal of Ayurveda and Integrated Medical Sciences* 2022; 7(8): 186–190.
- [5] Tiwari LN, Vijayalaxmi M, Shailaja U, Bhandari M. Management of umbilical granuloma through chemical cauterisation (Kshara karma) — A case study. *Journal of Ayurveda and Integrative Medicine* 2021; 12(1): 169–171.
- [6] Jawanjal P, Patgiri B. Therapeutics aspects of Apamarga Kshara (Herbomineral Formulation) in Ayurveda — A review. *Ayuhom* 2021; 8(2): 51–56.
- [7] Shekokar AV, Ukhalkar VP. Critical Review on Ksharaplota and its Therapeutic Aspects. *Journal of Drug Delivery and Therapeutics* 2019; 9(1-s): 510–515.
- [8] Ravishankar A, Prasanth BK. Pratisaraneeya Kshara — potent weapon against Dushtavrana. *Int Ayu Med J* 2013; 1: 1–7.
- [9] Raj P, Mishra I, Swapna B, Kumar PH. A Case Study on Effective Management of Abhayantra Arsha by Kshara Karma. *International Journal of Ayurveda and Pharma Research* 2021; 9(Suppl 1): 70–72.
- [10] Kaviraj Ambikadutta Shastri. Sushruta Samhita of Acharya Sushruta, Sutra Sthana 18/11-15 (Reprinted, 2017). Chaukhambha Sanskrit Sansthan, Varanasi: 46–48.
- [11] ShrutiPandey A. A critical review on historical aspects of Kshara. *Int. J. Res. Ayurveda Pharm.* 2016; 7(Suppl 3): 64–69.
- [12] Paradakar HS (Ed.). Ashtanga Hridaya. Chaukhambha Surbharti Prakashan, Varanasi, 2007: 643.
- [13] Chakrpanidatta IT. Chakradutta, Reprint edition, Ch. 45(10): 268.
- [14] Nanda SK. Mucocele of the oral cavity — A review. *J Oral Maxillofac Pathol* 2019; [literature reviewed].