Oral Cancer: A Comprehensive Review of Risk Factors, Early Detection, Prevention and Treatment

Shaikh Mumtaj[1], Salunke Radha[2], Rohokale Dnyaneshwari[3], Sonawane Soniya[4], Bangar Vilas[5]
[1,2,3,4]*Hon. Shri. Babanrao Pachpute Vichardhara Trust's, Group of institution Faculty of pharmacy Kashti*
[5]*Hon. Shri. Babanrao Pachpute Vichardhara Trust's, Parikrama Diploma in Pharmaceutical Science's, Kashti*

***Abstract*—Oral cancer is an important global health problem and represents a substantial proportion of cancers occurring in the head and neck region. Oral squamous cell carcinoma (OSCC) is the predominant histological type of oral malignancy. Tobacco use, smokeless tobacco, areca nut and betel quid consumption, alcohol use, human papillomavirus infection, poor oral hygiene, dietary factors, chronic irritation and genetic alterations have been associated with oral carcinogenesis. The disease frequently remains asymptomatic or presents with nonspecific oral lesions during its early stages, contributing to delayed diagnosis. Early identification of potentially malignant oral disorders and malignant lesions is therefore important for improving clinical outcomes.**

Conventional clinical oral examination followed by biopsy and histopathological examination remains central to diagnosis. Advances in oral cytology, salivary biomarkers, molecular diagnostics, optical imaging, liquid biopsy and artificial intelligence have created opportunities for complementary approaches to early detection. However, current evidence indicates that most emerging techniques should complement rather than replace clinical examination and histopathology. Treatment depends on tumour site, stage, depth of invasion, nodal involvement and patient-related factors and may involve surgery, radiotherapy, chemotherapy, targeted therapy and immunotherapy.

Prevention remains a major component of oral-cancer control. Tobacco and areca-nut cessation, reduction of alcohol exposure, improvement of oral health, public awareness and timely referral of suspicious lesions can contribute to reducing disease burden. Pharmacists and other healthcare professionals can support health education, tobacco-cessation counselling, recognition of warning signs and appropriate referral. This review summarizes recent evidence on the epidemiology, risk factors, pathogenesis, clinical manifestations, diagnosis, biomarkers, staging, treatment, prevention and emerging technologies in oral cancer.

***Index Terms*—Oral cancer; Oral squamous cell carcinoma; Risk factors; Tobacco; Areca nut; Early detection; Biomarkers; Diagnosis; Immunotherapy; Prevention.**

I. INTRODUCTION

Oral cancer refers to malignant neoplasms arising in the oral cavity, including the lip, tongue, buccal mucosa, gingiva, floor of the mouth, hard palate and other oral structures. Squamous cell carcinoma accounts for the great majority of oral cavity malignancies. OSCC is characterized by invasive growth, local tissue destruction and the potential for regional lymph-node and distant metastasis.

Oral cancer continues to represent an important public-health problem because many patients are diagnosed at relatively advanced stages. Recent reviews emphasize the continuing importance of tobacco, alcohol, areca nut and other preventable exposures, together with the need for greater public awareness and early clinical examination. [1-4] In India, the burden is particularly important because tobacco-containing products and areca-nut preparations are widely used in several populations. A national analysis using Global Burden of Disease data from 1990–2021 demonstrated substantial oral-cancer burden and considerable geographic variation across Indian states. [5]

The clinical appearance of early oral cancer may resemble benign or inflammatory lesions. Persistent ulcers, red or white patches, unexplained swelling, induration, restricted mouth opening, bleeding or changes in sensation should therefore receive appropriate clinical assessment. Early identification of potentially malignant oral disorders may provide an

opportunity for intervention before invasive cancer develops.

Although biopsy and histopathology remain fundamental diagnostic methods, research has expanded toward minimally invasive and non-invasive techniques. These include brush cytology, salivary biomarkers, optical imaging, molecular assays, liquid biopsy and artificial intelligence-assisted image analysis. [6-10] Recent evidence nevertheless indicates that many adjunctive technologies have insufficient evidence to replace conventional clinical examination and biopsy. [8,11]

The objective of this review is to provide a comprehensive and updated overview of oral cancer, with emphasis on risk factors, pathogenesis, potentially malignant disorders, clinical manifestations, diagnosis, biomarkers, staging, treatment, prevention and emerging diagnostic technologies.

II. EPIDEMIOLOGY OF ORAL CANCER

Oral cavity and lip cancers contribute significantly to the worldwide cancer burden. Their distribution varies considerably according to geographical region, sex, age, tobacco exposure, alcohol consumption and areca-nut use.

The South and South-East Asian region has a particularly important burden of oral cancer. Recent GLOBOCAN-based analyses have demonstrated substantial incidence and mortality in the region, with variations according to anatomical site and population. [12]

India represents an important setting for oral-cancer research and prevention. A 2024 systematic analysis based on GBD 2021 data evaluated incidence, mortality, disability-adjusted life years and prevalence across Indian states from 1990 to 2021. The analysis identified oral cancer as a major health burden and highlighted the importance of risk-factor control. [5]

Table 1. Major epidemiological characteristics of oral cancer

Parameter	Description
Major histological type	Oral squamous cell carcinoma
Common anatomical sites	Tongue, buccal mucosa, floor of mouth, gingiva, lip
Important risk factors	Tobacco, areca nut, betel quid, alcohol
Important additional factors	HPV, poor oral health, diet, genetic susceptibility
High-burden region	South and South-East Asia
Important prevention strategy	Control of modifiable risk factors
Important diagnostic principle	Clinical examination followed by biopsy when indicated

The epidemiological pattern has changed in some populations as smoking prevalence has declined, while other exposures and demographic factors continue to influence disease patterns. [2,13]

III. ANATOMICAL SITES AND CLASSIFICATION

Oral cancer may arise in different anatomical locations.

3.1 Lip

Cancer of the lip may involve the upper or lower lip. Sun exposure is particularly relevant to cancers of the external lip.

3.2 Tongue

The lateral border and ventral surface of the tongue are important sites for oral squamous cell carcinoma.

3.3 Buccal mucosa

The inner cheek is an important site, particularly in populations where smokeless tobacco and areca-nut products are used.

3.4 Floor of the mouth

The floor of the mouth contains a relatively thin mucosa and may be affected by tobacco and alcohol-related carcinogenesis.

3.5 Gingiva and alveolar mucosa

Malignancies can develop in the gingival and alveolar regions and may occasionally involve underlying bone.

3.6 Palate

The hard and soft palate may also be affected.

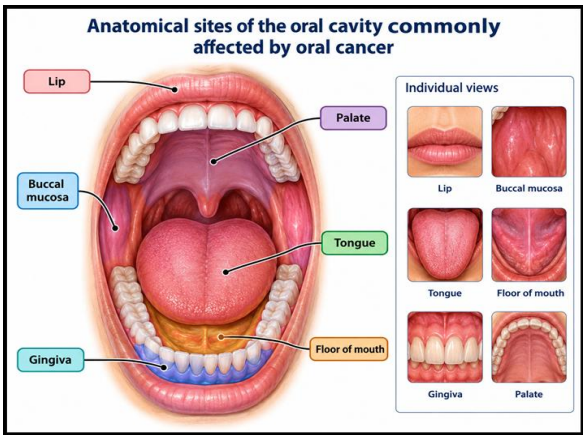

Figure 1. Anatomical sites of the oral cavity commonly affected by oral cancer.

Suggested illustration: labelled diagram showing lip, buccal mucosa, tongue, floor of mouth, gingiva and palate.

IV. MAJOR RISK FACTORS

Oral carcinogenesis is multifactorial. Several environmental, behavioural, infectious and genetic factors interact over time.

4.1 Tobacco

Tobacco smoking is a major established risk factor for oral cancer. Tobacco smoke contains numerous carcinogenic substances capable of producing DNA damage, oxidative stress and chronic inflammation. Both duration and intensity of exposure contribute to cumulative risk.

4.2 Smokeless tobacco

Smokeless tobacco products may expose the oral mucosa to carcinogenic compounds for prolonged periods. Their use is particularly relevant in South Asian populations.

4.3 Areca nut and betel quid

Areca-nut chewing is a particularly important risk factor in South and South-East Asia. Evidence from human studies demonstrates a substantial association between areca-nut exposure and oral cancer, with risk increasing according to duration and frequency of chewing. [14]

Areca nut is classified by IARC as a Group 1 carcinogenic exposure. Chronic use may also contribute to oral submucous fibrosis, an important potentially malignant disorder.

4.4 Alcohol

Alcohol consumption is associated with increased risk of oral and upper aerodigestive tract cancers. Alcohol may act through several mechanisms, including mucosal irritation and generation of acetaldehyde.

4.5 Human papillomavirus

HPV has an established role in some head and neck cancers, although its contribution differs according to anatomical site. HPV-associated disease is particularly important in the oropharynx; its role in conventional oral-cavity OSCC is more complex and should not be considered equivalent to HPV-driven oropharyngeal cancer.

4.6 Poor oral health

Poor oral hygiene, chronic inflammation and inadequate dental care have been investigated as potential contributors to oral-cancer risk. Their effects may interact with established behavioural risk factors.

Table 2. Major risk factors and possible mechanisms

Risk factor	Possible mechanism
Smoking	DNA damage, oxidative stress, carcinogen exposure
Smokeless tobacco	Direct mucosal exposure to carcinogens
Areca nut	Genotoxicity, oxidative stress, fibrosis
Betel quid	Combined exposure to carcinogenic constituents
Alcohol	Acetaldehyde formation and mucosal effects
HPV	Viral oncogene-mediated cellular dysregulation in susceptible sites
Poor oral health	Chronic inflammation and local environmental changes
Dietary imbalance	Altered antioxidant and inflammatory pathways
Genetic susceptibility	Altered DNA repair and tumour-control pathways

The interaction between multiple risk factors is important.

Tobacco and alcohol may have synergistic effects, while areca-nut exposure represents a major independent risk in affected populations. [3,14]

V. PATHOGENESIS OF ORAL CANCER

Oral carcinogenesis is a multistep process in which normal epithelial cells progressively acquire molecular and phenotypic abnormalities.

The general sequence can be represented as:
Risk exposure → molecular damage → epithelial alteration → dysplasia → carcinoma in situ/invasive carcinoma → local invasion → lymphatic/distant metastasis

Carcinogenic exposure may cause DNA damage and oxidative stress. Cells with accumulated molecular abnormalities may acquire growth advantages and evade normal mechanisms of apoptosis.

Important biological processes include:

- Sustained proliferative signalling
- Resistance to apoptosis
- Genomic instability
- Tumour-promoting inflammation
- Angiogenesis
- Immune evasion
- Invasion of surrounding tissues
- Lymphatic dissemination
- Metastasis

The tumour microenvironment also contributes to disease progression. Interactions between tumour cells, fibroblasts, immune cells, extracellular matrix and signalling molecules can influence invasion and therapeutic response. [15,16]

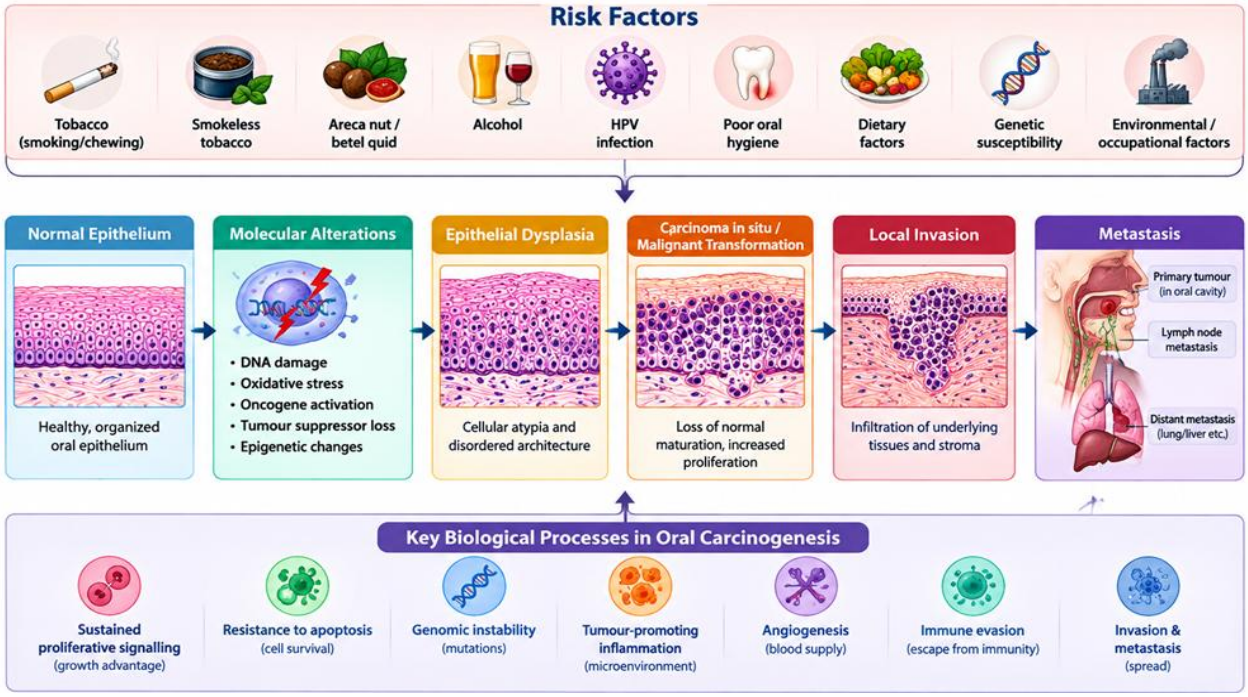

Figure 2. Simplified multistep pathway of oral carcinogenesis.

Risk factors initiate molecular alterations followed by epithelial dysplasia, malignant transformation, local invasion and possible metastasis.

VI. ORAL POTENTIALLY MALIGNANT DISORDERS

Oral potentially malignant disorders (OPMDs) are mucosal conditions associated with an increased risk of developing oral cancer.

Important examples include:

- Leukoplakia
- Erythroplakia
- Oral submucous fibrosis
- Selected forms of oral lichen planus
- Other clinically defined potentially malignant lesions

The probability of malignant transformation differs between disorders and depends on clinical and histopathological characteristics.

Oral submucous fibrosis is especially important in regions where areca-nut products are commonly consumed.

Prevention of exposure and early clinical management are important components of oral-cancer prevention. [17]

Table 3. Selected potentially malignant disorders

Disorder	Typical clinical feature	Important consideration
Leukoplakia	Predominantly white patch	Requires assessment of dysplasia/malignant potential
Erythroplakia	Red mucosal lesion	Often requires urgent evaluation
Oral submucous fibrosis	Progressive mucosal stiffness/restricted opening	Strongly associated with areca-nut exposure
Selected lichen planus lesions	Reticular, erosive or mixed lesions	Requires appropriate clinical follow-up

VII. CLINICAL FEATURES OF ORAL CANCER

The clinical presentation varies according to tumour location and stage.

Common warning signs include:

1. Persistent oral ulcer
2. Red or white patch
3. Unexplained oral swelling
4. Persistent pain
5. Difficulty chewing
6. Difficulty swallowing
7. Restricted mouth opening
8. Unexplained bleeding
9. Altered sensation
10. Loose tooth without an obvious dental cause
11. Persistent neck swelling
12. Change in speech

A persistent lesion should not automatically be assumed to be cancer, because many benign conditions can produce similar findings. However, suspicious or persistent lesions require professional assessment.

Table 4. Clinical features and appropriate response

Clinical feature	Possible significance	Appropriate action
Persistent ulcer	Possible malignant or potentially malignant lesion	Clinical examination
Red patch	May have increased malignant potential	Prompt evaluation
White patch	May represent leukoplakia or other lesion	Clinical assessment
Lump/swelling	Possible neoplastic lesion	Examination and imaging/biopsy if indicated
Restricted mouth opening	May occur in OSMF or advanced disease	Specialist evaluation
Neck swelling	Possible lymph-node involvement	Clinical and imaging assessment
Persistent pain	Nonspecific but concerning if persistent	Professional assessment

VIII. DIAGNOSIS AND EARLY DETECTION

8.1 Clinical oral examination

Clinical examination remains the first and most important step in evaluating oral mucosal abnormalities. It involves inspection and palpation of the oral cavity and relevant regional lymph nodes.

A 2026 evidence-informed guideline recommends clinical oral examination in adults and emphasizes that biopsy remains the reference standard for definitive diagnosis of oral potentially malignant disorders and OSCC. [11]

8.2 Biopsy and histopathology

Incisional or excisional biopsy may be performed according to lesion size, location and clinical circumstances. Histopathological examination determines whether malignancy is present and provides information about tumour differentiation and other pathological characteristics.

8.3 Cytology

Brush cytology is a minimally invasive technique that collects epithelial cells for cytological evaluation. It may be useful as an adjunct but does not replace biopsy when definitive tissue diagnosis is required.

8.4 Vital staining

Toluidine blue and other staining techniques have been investigated to assist in identifying suspicious lesions. However, evidence does not support using adjunctive staining as a replacement for conventional clinical examination and biopsy. [8]

IX. NON-INVASIVE AND EMERGING DIAGNOSTIC METHODS

Recent research has focused on less invasive approaches that could complement clinical examination.

These include:

9.1 Salivary biomarkers

Saliva is attractive because it can be collected non-invasively. Investigated biomarkers include proteins, cytokines, enzymes, nucleic acids and metabolites.

A 2024 systematic review and network meta-analysis assessed 94 salivary biomarkers across four meta-analyses and identified several promising candidates, including MMP-9 and chemerin. [9]

9.2 Liquid biopsy

Liquid biopsy approaches investigate circulating tumour DNA, RNA, extracellular vesicles and other molecular signals in body fluids.

9.3 Molecular biomarkers

Potential biomarkers may provide information concerning diagnosis, prognosis and treatment response.

9.4 Optical imaging

Optical techniques can potentially identify tissue alterations that are not readily apparent under conventional illumination.

9.5 Artificial intelligence

AI and machine-learning models are increasingly being investigated for analysis of clinical photographs, histopathology slides and imaging data.

Recent systematic reviews report promising diagnostic performance, but heterogeneity, dataset limitations, external validation and clinical implementation remain important challenges. [18-22]

Table 5. Emerging diagnostic technologies

Technology	Potential application	Current limitation
Salivary biomarkers	Non-invasive detection	Need standardization/validation
Brush cytology	Cellular assessment	May require biopsy confirmation
Optical imaging	Lesion identification	Variable evidence
Liquid biopsy	Molecular detection	Limited routine clinical implementation
AI image analysis	Screening/diagnostic assistance	Dataset bias and external validation
Molecular biomarkers	Diagnosis/prognosis	Standardization required

X. BIOMARKERS IN ORAL CANCER

Biomarkers may be useful for diagnosis, prognosis, monitoring or treatment selection.

Important categories include:

- Protein biomarkers
- Cytokines
- Enzymes
- MicroRNAs
- Long non-coding RNAs
- DNA methylation markers
- Circulating tumour DNA
- Tumour-associated proteins
- Immunohistochemical markers

Examples investigated in OSCC include Ki-67, HSP60, Survivin, E-cadherin and PD-L1. A 2026 systematic review concluded that these biomarkers may complement conventional histopathology and potentially contribute to diagnostic and prognostic stratification, although further multicentre validation is required. [23]

Salivary cytokines such as IL-1β, IL-6, IL-8, IL-1RA, interferon-γ, TNF-related cytokines and MMP-9 have also been investigated. [24]

Table 6. Examples of investigated oral-cancer biomarkers

Biomarker	Investigated role
Ki-67	Cellular proliferation
E-cadherin	Cell adhesion/tumour progression
PD-L1	Immune checkpoint/therapy selection
Survivin	Apoptosis resistance

Biomarker	Investigated role
HSP60	Tumour biology/prognosis
MMP-9	Invasion and salivary detection
IL-1β	Inflammation/diagnostic research
IL-6	Inflammation/diagnostic research
IL-8	Inflammation/angiogenesis
miRNAs	Molecular regulation/biomarker research

XI. STAGING OF ORAL CANCER

Staging describes the anatomical extent of cancer and assists treatment planning and prognosis.
The TNM system includes:

- T: Primary tumour characteristics
- N: Regional lymph-node involvement
- M: Distant metastasis

For oral cavity cancer, depth of invasion is an important pathological parameter and has been incorporated into contemporary staging considerations. [25]

Table 7. Simplified TNM concept

Component	Meaning
T	Size and local extent of primary tumour
N	Regional lymph-node involvement
M	Distant metastasis
Stage I–II	Generally localized disease
Stage III–IV	More advanced/local or regional disease

Exact staging should be performed using the current applicable AJCC/UICC staging system rather than simplified descriptions in a student review.

XII. PREVENTION OF ORAL CANCER

Prevention is an essential component of oral-cancer control.

12.1 Tobacco control

Avoiding tobacco use is one of the most important preventable measures.

12.2 Areca-nut cessation

Because areca nut is an established carcinogenic exposure, reducing and eliminating its use is particularly important in high-risk populations. [14]

12.3 Alcohol reduction

Reducing alcohol exposure can contribute to lowering the risk of several cancers.

12.4 Oral hygiene

Regular dental care and appropriate oral hygiene should be promoted.

12.5 Healthy lifestyle

Adequate fruit and vegetable consumption, physical activity and general health maintenance are beneficial for overall health.

12.6 Awareness

Public education should emphasize warning signs and the importance of timely professional assessment. (26)

XIII. CHALLENGES IN ORAL-CANCER CONTROL

Several challenges remain:

- Late presentation
- Limited public awareness
- Continued tobacco use
- Areca-nut consumption
- Limited access to specialist services
- Diagnostic delays
- Cost of advanced technologies
- Lack of standardized biomarkers
- Variability between AI datasets
- Limited prospective validation of emerging technologies
- Treatment-related functional and psychological consequences

Recent systematic reviews demonstrate that emerging diagnostic technologies are promising but heterogeneous, and high-quality prospective validation remains necessary. [8,10,18-22]

XIV. FUTURE PERSPECTIVES

Future research is likely to focus on integrating conventional pathology with molecular and digital technologies.
Potential directions include:

- Standardized salivary biomarker panels
- Multi-biomarker diagnostic models
- Liquid biopsy

- AI-assisted oral screening
- Digital pathology
- Portable point-of-care devices
- Precision immunotherapy
- Personalized risk prediction
- Integration of clinical and molecular datasets

The most useful future diagnostic systems are likely to complement rather than immediately replace conventional examination and histopathological diagnosis. The 2026 evidence-informed guideline specifically emphasizes clinical examination and retains biopsy as the reference standard for definitive diagnosis. [11]

XV. CONCLUSION

Oral cancer, particularly oral squamous cell carcinoma, remains an important public-health problem. Tobacco, smokeless tobacco, areca nut, betel quid and alcohol are major preventable risk factors, while genetic, infectious, inflammatory and environmental factors may also contribute to carcinogenesis.

Early recognition is essential because suspicious oral lesions can initially appear nonspecific. Clinical oral examination remains the foundation of early detection, while biopsy and histopathological examination remain central to definitive diagnosis. Salivary biomarkers, cytology, optical imaging, liquid biopsy and artificial intelligence represent promising areas of research. However, current evidence supports their use primarily as complementary approaches rather than replacements for established diagnostic methods.

Treatment depends on tumour site and stage and may involve surgery, radiotherapy, chemotherapy, targeted therapy and immunotherapy. Advances in molecular diagnostics and precision medicine may further improve individualized treatment.

Prevention remains particularly important. Reduction of tobacco and areca-nut exposure, responsible alcohol use, improved oral health, public education and timely professional evaluation can contribute to reducing oral-cancer burden. Pharmacists and other healthcare professionals can support these activities through health education, risk-factor counselling, early recognition and referral.

Overall, an integrated approach combining prevention, early clinical detection, accurate histopathological diagnosis, appropriate multidisciplinary treatment and emerging molecular/digital technologies offers an important pathway toward improved oral-cancer control.

REFERENCES

[1] Gormley, M., Gray, E., Richards, C., Gormley, A., Richmond, R. C., Vincent, E. E., et al., "An update on oral cavity cancer: epidemiological trends, prevention strategies and novel approaches in diagnosis and prognosis," *Community Dent. Health*, vol. 39, no. 3, pp. 197–205, 2022, doi: 10.1922/CDH_00032Gormley09.

[2] Jagadeesan, D., Sathasivam, K. V., Fuloria, N. K., Balakrishnan, V., Khor, G. H., Ravichandran, M., et al., "Comprehensive insights into oral squamous cell carcinoma: diagnosis, pathogenesis, and therapeutic advances," Pathol. Res. Pract., vol. 261, Art. no. 155489, 2024, doi: 10.1016/j.prp.2024.155489.

[3] Chamoli, A., Gosavi, A. S., Shirwadkar, U. P., Wangdale, K. V., Behera, S. K., Kurrey, N. K., et al., "Overview of oral cavity squamous cell carcinoma: risk factors, mechanisms, and diagnostics," Oral Oncol., vol. 121, Art. no. 105451, 2021, doi: 10.1016/j.oraloncology.2021.105451.

[4] Pan, C. and Z. Rizvi, "Oral cancer: what the general surgeon should know," Surg. Clin. North Am., vol. 102, no. 2, pp. 309–324, 2022, doi: 10.1016/j.suc.2021.12.007.

[5] Akashanand, Zahiruddin, Q. S., Jena, D., Ballal, S., Kumar, S., Bhat, M., et al., "Burden of oral cancer and associated risk factors at national and state levels: a systematic analysis from the global burden of disease in India, 1990–2021," Oral Oncol., vol. 159, Art. no. 107063, 2024, doi: 10.1016/j.oraloncology.2024.107063.

[6] Wang, S., et al., "Current advances in noninvasive methods for the diagnosis of oral squamous cell carcinoma: a review," Eur. J. Med. Res., 2023, doi: 10.1186/s40001-022-00916-4.

[7] Menditti, D., Santagata, M., Imola, G., Staglianò, S., Vitagliano, R., Boschetti, C. E., et al., "Personalized medicine in oral oncology: imaging methods and biological markers to support diagnosis of oral squamous cell carcinoma: a narrative literature review," J. Pers. Med., vol. 13,

no. 9, Art. no. 1397, 2023, doi: 10.3390/jpm13091397.

[8] Lau, J., Guru, O., Warnakulasuriya, S., Balasubramaniam, R., Frydrych, A., and O. Kujan, "Adjunctive aids for the detection of oral squamous cell carcinoma and oral potentially malignant disorders: a systematic review of systematic reviews," Jpn. Dent. Sci. Rev., vol. 60, pp. 53–72, 2024, doi: 10.1016/j.jdsr.2023.12.004.

[9] Khijmatgar, S., Yong, J., Rübsamen, N., Lorusso, F., Rai, P., Cenzato, N., et al., "Salivary biomarkers for early detection of oral squamous cell carcinoma and head/neck squamous cell carcinoma: a systematic review and network meta-analysis," Jpn. Dent. Sci. Rev., vol. 60, pp. 32–39, 2024, doi: 10.1016/j.jdsr.2023.10.003.

[10] Groenevelt, M. C. C., Meulenbroeks, L., Brakenhoff, R. H., Poell, J. B., Fransen, M. P., Zwinderman, A. H., et al., "Non-invasive detection and monitoring of oral squamous cell carcinoma and oral potentially malignant disorders: an umbrella review on diagnostic accuracy," Clin. Oral Investig., vol. 30, no. 9, 2026, doi: 10.1007/s00784-026-07109-x.

[11] Bhosale, A. S., Martins-Pfeifer, C., Verdugo-Paiva, F., Urquhart, O., Carrasco-Labra, A., Pimentel, J., et al., "Living evidence-informed guideline on the early detection of oral squamous cell carcinoma and potentially malignant disorders: light-based adjuncts to determine the need for biopsy, Version 2026 1.0," J. Am. Dent. Assoc., vol. 157, no. 9, pp. 968–979, 2026, doi: 10.1016/j.adaj.2026.04.010.

[12] Warnakulasuriya, S. and A. M. Filho, "Oral cancer in the South and South-East Asia region, 2022: incidence and mortality," Oral Dis., 2025, doi: 10.1111/odi.15369.

[13] Capote-Moreno, A., Brabyn, P., Muñoz-Guerra, M. F., Sastre-Pérez, J. S., Escorial-Hernandez, V., Rodríguez-Campo, F. J., et al., "Oral squamous cell carcinoma: epidemiological study and risk factor assessment based on a 39-year series," Int. J. Oral Maxillofac. Surg., vol. 49, no. 12, pp. 1525–1534, 2020, doi: 10.1016/j.ijom.2020.03.009.

[14] Gupta, B., Johnson, N. W., and N. Kumar, "Areca nut and oral cancer: evidence from studies conducted in humans," J. Dent. Res., 2022, doi: 10.1177/00220345221092751.

[15] Tan, Y., Wang, Z., Xu, M., Li, B., Huang, Z., Qin, S., et al., "Oral squamous cell carcinomas: state of the field and emerging directions," Cell. Mol. Life Sci., vol. 80, no. 1, Art. no. 44, 2023, doi: 10.1038/s41368-023-00249-w.

[16] Sharma, Y. and K. Bala, "Role of Toll like receptor in progression and suppression of oral squamous cell carcinoma," Oncol. Rev., vol. 14, no. 1, Art. no. 456, 2020, doi: 10.4081/oncol.2020.456.

[17] Pentenero, M., et al., "Overview of oral potentially malignant disorders: from risk factors to specific therapies," Oral Oncol., 2021, PMID: 34359597.

[18] Khanagar, S. B., Naik, S., Al Kheraif, A. A., Vishwanathaiah, S., Maganur, P. C., Alhazmi, Y., et al., "Application and performance of artificial intelligence technology in oral cancer diagnosis and prediction of prognosis: a systematic review," Diagnostics, vol. 11, no. 6, Art. no. 1004, 2021, doi: 10.3390/diagnostics11061004.

[19] Alabi, R. O., Youssef, O., Pirinen, M., Elmusrati, M., Mäkitie, A. A., Leivo, I., et al., "Machine learning in oral squamous cell carcinoma: current status, clinical concerns and prospects for future—a systematic review," Artif. Med., vol. 115, Art. no. 102060, 2021, doi: 10.1016/j.artmed.2021.102060.

[20] Chu, C. S., Lee, N. P., Ho, J. W. K., Choi, S. W., and P. J. Thomson, "Deep learning for clinical image analyses in oral squamous cell carcinoma: a review," JAMA Otolaryngol. Head Neck Surg., vol. 147, no. 10, pp. 893–900, 2021, doi: 10.1001/jamaoto.2021.2028.

[21] Veeraraghavan, V. P., Minervini, G., Russo, D., Cicciù, M., and V. Ronsivalle, "Assessing artificial intelligence in oral cancer diagnosis: a systematic review," J. Craniofac. Surg., 2024, doi: 10.1097/SCS.0000000000010663.

[22] Sahoo, R. K., Sahoo, K. C., Dash, G. C., Kumar, G., Baliarsingh, S. K., Panda, B., et al., "Diagnostic performance of artificial intelligence in detecting oral potentially malignant disorders and oral cancer using medical diagnostic imaging: a systematic review and meta-analysis," Front. Oral Health, vol. 5, Art. no. 1494867, 2024, doi: 10.3389/froh.2024.1494867.

[23] López-Galindo, M. and M. D. Sousa-Roques, "Biomarkers in oral squamous cell carcinoma: a

systematic review," Med. Oral Patol. Oral Cir. Bucal, vol. 31, no. 1, pp. e82–e88, 2026, doi: 10.4317/medoral.27565.

[24] Rengasamy, G., Kasirajan, H. S., Veeraraghavan, V. P., Ramani, P., Cervino, G., and G. Minervini, "Salivary cytokines as a biomarker for diagnosis, prognosis and treatment of oral squamous cell carcinoma: a systematic review," Dent. Med. Probl., vol. 62, no. 2, pp. 351–359, 2025, doi: 10.17219/dmp/186664.

[25] Almangush, A., Mäkitie, A. A., Triantafyllou, A., de Bree, R., Strojan, P., Rinaldo, A., et al., "Staging and grading of oral squamous cell carcinoma: an update," Oral Oncol., vol. 107, Art. no. 104799, 2020, doi: 10.1016/j.oraloncology.2020.104799.

[26] Bouvard, V., Nethan, S. T., Singh, D., Warnakulasuriya, S., Mehrotra, R., Chaturvedi, A. K., et al., "IARC perspective on oral cancer prevention," N. Engl. J. Med., vol. 387, no. 21, pp. 1999–2005, 2022, doi: 10.1056/NEJMsr2210097.

[27] Subash, A., Bylapudi, B., Thakur, S., and V. U. Rao, "Oral cancer in India, a growing problem: is limiting the exposure to avoidable risk factors the only way to reduce the disease burden?" Oral Oncol., vol. 125, Art. no. 105677, 2022, doi: 10.1016/j.oraloncology.2021.105677.

[28] Bugshan, A. and I. Farooq, "Oral squamous cell carcinoma: metastasis, potentially associated malignant disorders, etiology and recent advancements in diagnosis," F1000Res., vol. 9, Art. no. 229, 2020, doi: 10.12688/f1000research.22941.1.

[29] Caruntu, A. and C. Caruntu, "Recent advances in oral squamous cell carcinoma," J. Clin. Med., vol. 11, no. 21, Art. no. 6406, 2022, doi: 10.3390/jcm11216406.

[30] Madera, M., Tirado Amador, L., and C. Leal Acosta, "Therapeutic options in unresectable oral squamous cell carcinoma: a systematic review," Cancer Manag. Res., vol. 13, pp. 6705–6719, 2021, doi: 10.2147/CMAR.S283204.

[31] Parak, U., Carvalho, A. L., Roitberg, F., and O. Mandrik, "Effectiveness of screening for oral cancer and oral potentially malignant disorders: a systematic review," Prev. Med. Rep., vol. 30, Art. no. 101987, 2022, doi: 10.1016/j.pmedr.2022.101987.

[32] Gyanchandani, A., Shukla, S., Vagha, S., Acharaya, S., and R. P. Kadu, "Diagnostic utility of cytokeratin 17 expression in oral squamous cell carcinoma: a review," Cureus, 2022, doi: 10.7759/cureus.27041.

[33] Pekarek, L., Garrido-Gil, M. J., Sánchez-Cendra, A., Cassinello, J., Pekarek, T., Fraile-Martinez, O., et al., "Emerging histological and serological biomarkers in oral squamous cell carcinoma: applications in diagnosis, prognosis evaluation and personalized therapeutics," Oncol. Rep., vol. 50, no. 6, 2023, doi: 10.3892/or.2023.8650.

[34] Binmadi, N. O. and Y. A. Mohamed, "Impact of worst pattern of invasion on prognosis of oral squamous cell carcinoma: a systematic review and meta-analysis," J. Int. Med. Res., vol. 51, no. 10, 2023, doi: 10.1177/03000605231206260.

[35] Menditti, D., Santagata, M., Imola, G., Staglianò, S., Vitagliano, R., Boschetti, C. E., et al., "Personalized medicine in oral oncology: imaging methods and biological markers to support diagnosis of oral squamous cell carcinoma," J. Pers. Med., vol. 13, no. 9, Art. no. 1397, 2023, doi: 10.3390/jpm13091397.

[36] Ibrahim, S. A., Ahmed, A. N. A., Elsersy, H. A., and I. M. H. Darahem, "Elective neck dissection in T1/T2 oral squamous cell carcinoma with N0 neck: essential or not? A systematic review and meta-analysis," Eur. Arch. Otorhinolaryngol., vol. 277, no. 6, pp. 1741–1752, 2020, doi: 10.1007/s00405-020-05866-3.

[37] Parak, U., Carvalho, A. L., Roitberg, F., and O. Mandrik, "Effectiveness of screening for oral cancer and oral potentially malignant disorders: a systematic review," Prev. Med. Rep., vol. 30, Art. no. 101987, 2022, doi: 10.1016/j.pmedr.2022.101987.

[38] Lau, J., Guru, O., Warnakulasuriya, S., Balasubramaniam, R., Frydrych, A., and O. Kujan, "Adjunctive aids for detection of oral squamous cell carcinoma and oral potentially malignant disorders: systematic review of systematic reviews," Jpn. Dent. Sci. Rev., vol. 60, pp. 53–72, 2024, doi: 10.1016/j.jdsr.2023.12.004.

[39] Li, J. W., Kot, W. Y., McGrath, C. P., Chan, B. W. A., Ho, J. W. K., and L. W. Zheng, "Diagnostic accuracy of artificial intelligence assisted clinical imaging in detection of oral potentially malignant disorders and oral cancer: a

systematic review and meta-analysis," 2024, vol. 110, no. 8, pp. 5034–5046, doi: 10.1097/JS9.0000000000001469.

[40] Alabi, R. O., et al., "Artificial intelligence and machine-learning approaches in oral squamous cell carcinoma diagnosis and prognosis: recent evidence and clinical considerations," literature published in the 2020–2024 period.