Breast Cancer: From Anatomy to Molecular Complexity an Integrated Review

Ruderansh[1], Tarun Sharma[2], Keshav Dhiman[3], Pravin Kumar[4], Vinay Pandit[5], M.S. Ashawat[6]
[1,2,3,4,5,6]*Department of Pharmaceutics, Laureate Institute of Pharmacy, Kathog, Kangra 176031*

***Abstract*—Breast cancer is one of the most common cancers worldwide and represents a diverse group of malignant diseases that develop from different cells and tissues of the breast. It occurs when breast cells undergo biological and molecular changes that result in uncontrolled growth and division. The development of breast cancer is influenced by multiple factors, including age, genetic background, family history, reproductive and hormonal factors, previous breast disease, and specific molecular characteristics. Among the important genetic risk factors, inherited mutations in the BRCA1 and BRCA2 genes are associated with an increased risk of breast cancer. Therefore, an understanding of breast anatomy, disease classification, risk factors, clinical symptoms, and molecular characteristics is essential for understanding the development and management of breast cancer. The breast is a complex anatomical structure composed mainly of glandular, connective, and adipose tissues. It also contains lobes, lobules, milk ducts, blood vessels, lymphatic vessels, lymph nodes, nerves, the nipple, and the areola. The glandular tissue is involved in milk production, while the milk ducts transport milk toward the nipple. Connective and adipose tissues provide structural support, protection, shape, and volume. The lymphatic system is clinically important because cancer cells may spread through lymphatic vessels to nearby lymph nodes and other tissues.**

Breast cancer includes several major types with different biological and clinical characteristics. Important types include invasive ductal carcinoma, invasive lobular carcinoma, ductal carcinoma in situ, triple-negative breast cancer, inflammatory breast cancer, and Paget's disease of the breast. Invasive ductal carcinoma develops in the cells lining the milk ducts and may invade surrounding breast tissue. Invasive lobular carcinoma originates in the milk-producing lobules and may not always produce a clearly defined lump. Ductal carcinoma in situ is considered a non-invasive or pre-invasive condition because abnormal cells remain within the milk ducts. Triple-negative breast cancer lacks estrogen receptors, progesterone receptors, and HER2 receptors, resulting in different therapeutic considerations. Inflammatory breast cancer is associated with lymphatic blockage and may present with swelling, redness, warmth, and skin thickening. Paget's disease mainly affects the nipple and areola and may produce itching, redness, scaling, crusting, or nipple discharge.

Breast cancer may present with a breast or underarm lump, persistent thickening, changes in breast size or shape, skin dimpling, redness, nipple changes, or unusual discharge. However, symptoms vary according to the type and stage of disease. Molecular pathways such as estrogen receptor signaling, HER2, EGFR-related pathways, RAS/MEK/ERK signaling, cell-cycle regulation, apoptosis, and pathways associated with invasion and metastasis have important roles in breast cancer biology. These molecular characteristics have supported the development of targeted therapeutic approaches. Endocrine therapies, including tamoxifen and aromatase inhibitors such as anastrozole, letrozole, and exemestane, are important treatment options for estrogen-dependent breast cancer.

***Index Terms*—Breast cancer; Breast anatomy; Cancer classification; Risk factors; Molecular pathways**

I. INTRODUCTION

Breast cancer is one of the most common types of cancer worldwide, with about 2.3 million new cases diagnosed each year. It develops from different biological and molecular changes in breast tissue. The risk of developing breast cancer depends on several factors, including the specific type of cancer and a person's genetic background. In particular, inherited mutations in the BRCA1 and BRCA2 genes are among the most important genetic factors that increase the risk of breast cancer. [1]

Breast cancer occurs when cells in the breast begin to grow and divide uncontrollably, forming a tumor. Different types of breast cancer exist, and they are classified based on the specific breast cells where the cancer first develops. [2]

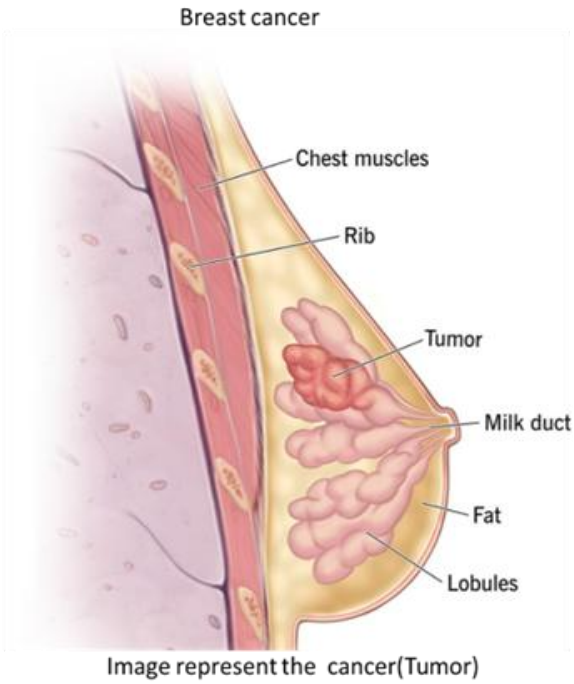

Fig 1

Targeted therapy has become an important approach in the treatment of breast cancer, especially for cancers that depend on estrogen to grow. One of the most commonly used treatments is tamoxifen, which blocks the action of estrogen receptors and has significantly improved survival rates, quality of life, and disease prevention over the past several decades. Other treatment options for estrogen-dependent breast cancer include aromatase inhibitors such as anastrozole, letrozole, and exemestane. These drugs reduce estrogen production by blocking the aromatase enzyme, thereby slowing the growth of cancer cells.

Advances in breast cancer treatment have also been achieved by combining targeted therapies with chemotherapy. In recent years, researchers have developed several monoclonal antibodies and small-molecule drugs that specifically target cancer-related pathways. Important molecular targets in breast cancer include the epidermal growth factor receptor (EGFR) family, vascular endothelial growth factor (VEGF) family, RAS/MEK/ERK signaling pathway, cell cycle and apoptosis regulators, estrogen receptors, pathways involved in invasion and metastasis, insulin-like growth factor signaling, and steroid hormone receptors. These targeted treatments help improve the effectiveness of therapy while reducing damage to healthy cells. [3]

II. ANATOMY OF BREAST

The breasts are a pair of mammary glands located on the front of the chest. They become fully developed in females after puberty, while in males they remain small and less developed. The breast plays an important role in milk production and breastfeeding. [4] In adult females, the breast is located on the front of the chest and extends from the 2nd to the 6th ribs. It stretches from the breastbone (sternum) near the center of the chest to the midaxillary line near the armpit. A small extension of breast tissue, called the axillary tail (Tail of Spence), extends upward and outward into the armpit area. The upper outer part of the breast, close to the armpit, is the area where breast tumors, both benign (non-cancerous) and malignant (cancerous), are most commonly found. [5]

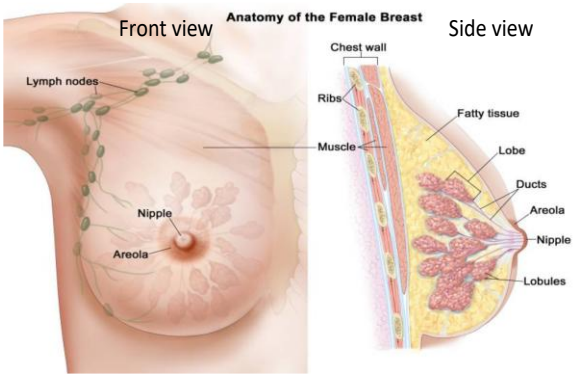

[6]

Fig 2

The breast is made up of three main types of tissue. Glandular tissue, also known as lobules, is responsible for producing milk during breastfeeding. Connective (fibrous) tissue supports the breast and holds the glandular and fatty tissues together. Fatty tissue fills the spaces between these tissues, gives the breast its shape, and largely determines its size. [7]

Part of Breast

Breast Structure	Description	Function
Adipose Tissue (Fatty Tissue)	Most of the breast is made up of fatty tissue, which extends from the collarbone to the armpit and covers the chest area.	Provides shape, size, support, and protection to the breast.

Lobes	Each breast contains about 15–20 sections called lobes, arranged around the nipple like spokes of a wheel.	Contain the milk-producing structures of the breast.
Lobules (Glandular Tissue)	Small groups of glands located within the lobes that produce milk after childbirth.	Produce and secrete milk for breastfeeding.
Milk (Mammary) Ducts	Thin tubes that connect the lobules to the nipple.	Transport milk from the lobules to the nipple during breastfeeding.
Nipples	The raised structure located at the center of the breast. Each nipple contains several milk ducts and many nerve endings.	Allows milk to leave the breast and provides sensory stimulation.
Areola	The darker circular area of skin surrounding the nipple. It contains special glands called Montgomery's glands.	Produces lubricating oil that protects the nipple and surrounding skin, especially during breastfeeding.
Blood Vessels	A network of vessels that carry blood throughout the breast and surrounding tissues.	Supply oxygen and nutrients to breast tissues and remove waste products.
Lymph Vessels	Tubes that are part of the lymphatic system and carry lymph fluid throughout the breast.	Help remove excess fluid and support the body's immune defense against infection.
Lymph Nodes	Small, bean-shaped organs located near the breast, especially in the armpit and chest area.	Filter lymph fluid and help the body fight infections and diseases.
Nerves	The breast, especially the nipple, contains many nerve endings that are highly sensitive.	Provide sensation such as touch, pressure, and temperature.

[6]

Type of breast cancer

1. Invasive (infiltrating) ductal carcinoma (IDC)
2. Lobular breast cancer
3. Ductal carcinoma in situ (DCIS)
4. Triple-negative breast cancer (TNBC)
5. Inflammatory breast cancer (IBC)
6. Paget's disease of breast

III. INVASIVE DUCTAL CARCINOMA

Invasive ductal carcinoma is a type of breast cancer that begins in the cells lining the milk ducts of the breast. The invasive ductal carcinoma can grow through the walls of the milk duct and spread into the surrounding breast tissue. If it left untreated, the cancer may enter the blood or lymphatic system and spread to other parts of the body.

The different types of invasive ductal carcinoma (IDC) are classified based on the hormone receptors present on or inside the cancer cells.

Hormone receptors are proteins found on or inside cells that can attach to hormones such as estrogen and progesterone. These hormones can help cancer cells grow. Knowing the hormone receptor status of a breast cancer helps doctors choose the most suitable and effective treatment. [8]

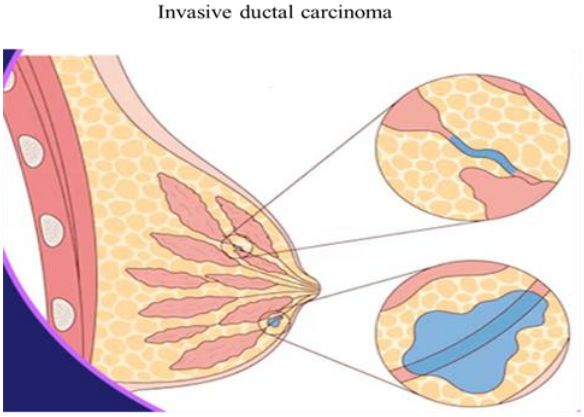

Fig 3

Type of invasive ductal carcinoma:

- Triple-negative breast cancer.
- HER2-positive (HER2+) breast cancer.
- ER-positive (ER+) breast cancer.
- PR-positive (PR+) breast cancer.

Symptoms of invasive ductal carcinoma (IDC)

- A noticeable change in size, shape, or overall appearance of the breast.
- The presence of a lump or mass in the breast, which may be as small as a pea.

- A persistent lump or thickened area in the breast or underarm that does not go away, even after the menstrual cycle.
- Changes in the skin of the breast or nipple, including dimpling, puckering, scaling, redness, or inflammation.
- A firm or hard, marble-like area that can be felt beneath the skin of the breast.
- Unusual nipple discharge, particularly clear or bloody fluid. [9]

IV. LOBULAR BREAST CANCER

Invasive lobular carcinoma (ILC) is a type of breast cancer that begins in the milk-producing glands (lobules) of the breast. It often grows slowly and is usually influenced by estrogen, the primary female hormone. Unlike some other breast cancers, ILC may not form a distinct lump, making it harder to notice in its early stages. As the cancer develops, it can spread through the breast tissue and to other parts of the body. ILC occurs when changes (mutations) in the genes cause normal, healthy breast cells to grow uncontrollably and become cancerous. [10]

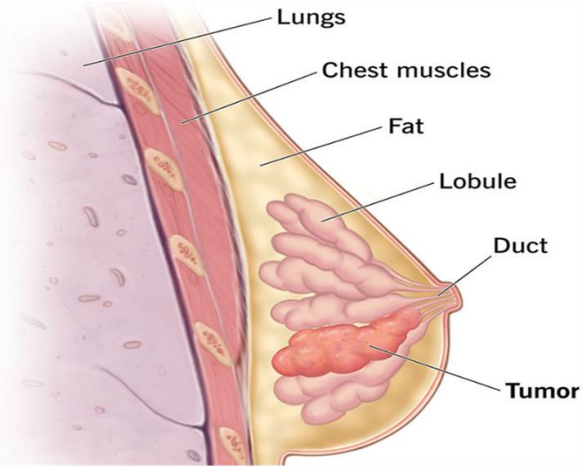

Invasive lobular carcinoma

Fig 4

Factors that increase the risk of lobular breast cancer:

- Age 55 years or older may increase the risk of developing breast cancer.
- Having the first child after the age if 30 or never having a full-term pregnancy is associated with an increased risk of breast cancer.
- A previous history of breast cancer increases the likelihood of developing breast cancer again.
- A family history of breast or ovarian cancer, particularly among close relatives, may increase an individual's risk.
- Lobular carcinoma in situ (LCIS) is a non-invasive breast condition that is associated with a higher risk of developing breast cancer.
- Inheriting genetic mutation, such as changes in the BRCA1 and BRCA2 genes, can significantly increase the risk of breast cancer.
- Menopause occurring after the age of 55 results in longer lifetime exposure to estrogen and may increase the risk of breast cancer.
- Beginning menstruation befor.
- Using certain types of hormone replacement therapy (HRT) to manage menopause symptoms. [11]

V. DUCTAL CARCINOMA IN SITU (DCIS)

Ductal carcinoma in situ (DCIS) is a very early stage of breast cancer that begins in the milk ducts of one or both breasts. The milk ducts are small tubes that carry milk from the milk-producing glands to the nipple during breastfeeding. In DCIS, abnormal cancer cells are found only inside the ducts and have not spread into the surrounding breast tissue. Because the cancer remains confined to the ducts, it is often called non-invasive or pre-invasive breast cancer. DCIS does not usually spread to other parts of the body. Although it is not life-threatening at this stage, treatment is important because it may develop into invasive breast cancer if left untreated.

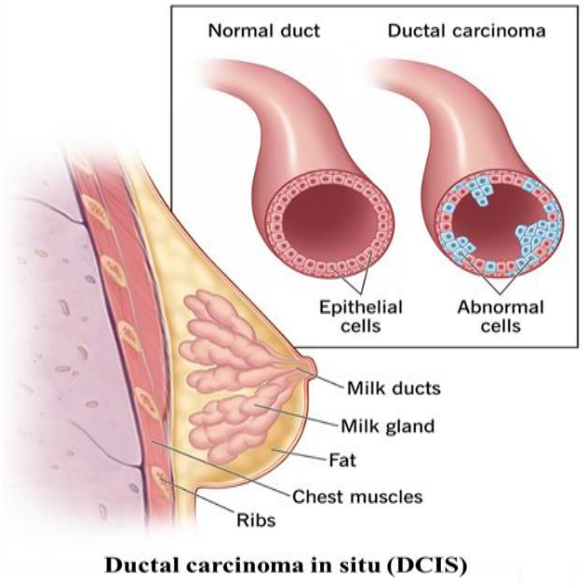

Ductal carcinoma in situ (DCIS)

Fig 4

Factor can increase the risk of ductal carcinoma in situ

- Family history of breast cancer
- Personal history of breast cancer
- Having atypical hyperplasia (abnormal breast cell growth)
- Starting menstrual periods before age 12. [12,13]

VI. TRIPLE-NEGATIVE BREAST CANCER (TNBC)

Triple-negative breast cancer (TNBC) gets its name because the cancer cells do not have three common receptors found in many other types of breast cancer: estrogen receptors, progesterone receptors, and HER2 receptors. These receptors normally help control the growth of breast cells and are often targeted by standard breast cancer treatments. Since TNBC cells lack these receptors, many treatments that are effective for other types of breast cancer do not work as well for TNBC. However, recent research has shown that combining certain cancer treatments may improve outcomes and help people with triple-negative breast cancer live longer.

Symptoms of triple-negative breast cancer:

- A mew lump or mass in breast.
- Breast pain or nipple pain.
- Skin of the breast gets dry, flaking, thickened or red. [14,15]

VII. INFLAMMATORY BREAST CANCER (IBC)

Inflammatory breast cancer (IBC) is a rare and aggressive type of breast cancer that grows and spreads quickly. It occurs when cancer cells block the lymph vessels in the breast, causing inflammation.



Inflammatory breast cancer

Fig 5

As a result, the breast may become swollen, warm, red, or discolored. The skin of the breast may also become thickened or develop a dimpled appearance similar to the skin of an orange. Because IBC grows rapidly, it can spread from the lymph vessels to nearby breast tissue, lymph nodes, and other parts of the body if not treated properly.

Symptoms that may be noticeable:

- Bruising or rash that spreads over one-third of breast.
- Inverted nipple or retracted nipple (a nipple that points inward).
- Skin discoloration that may look red or pink or purple, depending on the skin tone. [16]

VIII. PAGET'S DISEASE OF BREAST

Paget's disease of the breast is a rare type of breast cancer that affects the skin of the nipple and sometimes the areola, the darker area surrounding the nipple. In some cases, it is limited to the nipple and is considered an early-stage breast cancer (ductal carcinoma in situ). In other cases, it may occur along with invasive breast cancer in the milk ducts of the same breast. This condition often looks similar to eczema or a skin rash, which can make it difficult to recognize at first. Common symptoms include itching, redness, scaling or flaking of the skin, raised patches on the nipple or areola, and discharge from the nipple. [17]

Symptoms of Paget's disease:

- Nipple itching that can turn to burning.
- Dry skin, flaking or scaling of the nipple or areola.
- Skin rash that might red, raised, crusting or bleeding.
- Inflammation and soreness. [18]

IX. CONCLUSION

Breast cancer is a complex and heterogeneous disease with considerable variation in its anatomical origin, biological characteristics, molecular profile, clinical presentation, and therapeutic requirements. The present review provides an integrated overview of breast cancer by connecting normal breast anatomy with major disease types, risk factors, symptoms, molecular mechanisms, and therapeutic approaches.

This integrated understanding is important because breast cancer cannot be considered a single uniform disease. Different subtypes may develop through different biological mechanisms and may require different approaches for diagnosis and treatment.

The normal breast consists of several important structural components, including glandular tissue, connective tissue, adipose tissue, lobes, lobules, milk ducts, blood vessels, lymphatic vessels, lymph nodes, nerves, nipple, and areola. These structures perform different physiological functions and provide the anatomical basis for understanding breast diseases. In particular, the lymphatic system has an important role in breast cancer because malignant cells can spread through lymphatic vessels and reach regional lymph nodes. Understanding the normal organization of breast tissue therefore provides a useful foundation for understanding tumor development and possible disease progression.

The major types of breast cancer discussed in this review include invasive ductal carcinoma, invasive lobular carcinoma, ductal carcinoma in situ, triple-negative breast cancer, inflammatory breast cancer, and Paget's disease of the breast. Each type demonstrates different characteristics. Invasive ductal carcinoma develops from the milk ducts and can extend into surrounding tissue. Invasive lobular carcinoma begins in the lobules and may be difficult to detect as a distinct lump. Ductal carcinoma in situ remains within the milk ducts and is considered a non-invasive or pre-invasive condition, although progression to invasive disease may occur. Triple-negative breast cancer does not express estrogen receptors, progesterone receptors, or HER2 receptors, which limits the use of therapies directed against these targets. Inflammatory breast cancer is associated with lymphatic involvement and may cause redness, swelling, warmth, and skin changes. Paget's disease primarily involves the nipple and areola and may resemble inflammatory or dermatological conditions.

The development of breast cancer is influenced by several risk factors. Genetic background, family history, age, reproductive factors, hormonal exposure, previous breast cancer, and certain breast conditions may contribute to disease risk. Inherited mutations in BRCA1 and BRCA2 are particularly important genetic factors. However, the presence of a risk factor does not necessarily mean that an individual will develop breast cancer. The disease results from a complex interaction of multiple biological and individual factors.

At the molecular level, breast cancer involves several signaling pathways and regulatory mechanisms. Estrogen receptor signaling, HER2, EGFR-related pathways, RAS/MEK/ERK signaling, cell-cycle regulation, apoptosis, and pathways involved in invasion and metastasis contribute to tumor development and progression. Understanding these mechanisms has supported the development of targeted and endocrine therapies. Aromatase inhibitors such as letrozole, anastrozole, and exemestane reduce estrogen production and are important therapeutic options for estrogen-dependent breast cancer.

REFERENCES

[1] S. Fernández-Carballido, R. Simancas-Herbada, C. Martin-Sabroso, and A. Torres-Suárez, "CBD loaded microparticles as a potential formulation to improve paclitaxel and doxorubicin-based chemotherapy in breast cancer," *Int. J. Pharm.*, vol. 574, p. 118916, 2020, doi: 10.1016/j.ijpharm.2019.118916.

[2] Centers for Disease Control and Prevention, "Breast cancer: About." [Online]. Available:

[3] C. M. Schlotter, U. Vogt, H. Allgayer, and B. Brandt, "Molecular targeted therapies for breast cancer treatment," *Breast Cancer Res.*, vol. 10, no. 4, pp. 211–212, 2008, doi: 10.1186/bcr2112.

[4] G. Bistoni and J. Farhadi, "Anatomy and physiology of the breast," in *Plastic and Reconstructive Surgery: Approaches and Techniques*, 1st ed., R. D. Farhadieh, N. W. Bulstrode, and S. Cugno, Eds. Hoboken, NJ, USA: John Wiley & Sons, 2015, pp. 479–485.

[5] National Breast Cancer Foundation, "Breast anatomy." [Online]. Available: Accessed: Sep. 5, 2023.

[6] PDQ Screening and Prevention Editorial Board, "Breast cancer screening (PDQ®): Patient version," in *PDQ Cancer Information Summaries* [Internet]. Bethesda, MD, USA: National Cancer Institute, 2002–2025. [Online]. Available: Accessed: Feb. 14, 2025.

[7] Susan G. Komen, "Breast anatomy." [Online]. Available: Accessed: Sep. 5, 2023.

[8] American Cancer Society, "Invasive breast cancer (IDC/ILC)." [Online]. Available: Updated: Nov. 19, 2021. Accessed: Jun. 27, 2024.

[9] American Society of Clinical Oncology, "Breast cancer: Introduction." [Online]. Available: Last reviewed: Oct. 2022. Accessed: Jun. 27, 2024.

[10] G. Corso, N. Fusco, E. Guerini-Rocco, et al., "Invasive lobular breast cancer: Focus on prevention, genetics, diagnosis, and treatment," *Semin. Oncol.*, vol. 51, nos. 3–4, pp. 106–122, 2024. [Online]. Available: Accessed: Apr. 21, 2025.
[11] National Breast Cancer Foundation (U.S.), "Invasive lobular carcinoma (ILC)." [Online]. Available: Updated: Dec. 2024. Accessed: Apr. 21, 2025.
[12] American Cancer Society, "Ductal carcinoma in situ (DCIS)." [Online]. Available: Last reviewed: Nov. 19, 2021. Accessed: Sep. 19, 2024.
[13] American Cancer Society, "Treatment of ductal carcinoma in situ (DCIS)." [Online]. Available: Last reviewed: Oct. 27, 2021. Accessed: Sep. 19, 2024.
[14] P. V. Bhardwaj, Y. Wang, E. Brunk, et al., "Advances in the management of early-stage triple-negative breast cancer," *Int. J. Mol. Sci.*, vol. 24, no. 15, p. 12478, 2023. [Online]. Available: Accessed: Apr. 23, 2025.
[15] B. Lu, E. Natarajan, H. R. Balaji Raghavendran, et al., "Molecular classification, treatment, and genetic biomarkers in triple-negative breast cancer: A review," *Technol. Cancer Res. Treat.*, vol. 22, Art. no. 15330338221145246, 2023. [Online]. Available: Accessed: Apr. 23, 2025.
[16] V. Chippa and H. Barazi, "Inflammatory breast cancer," in *StatPearls* [Internet]. Treasure Island, FL, USA: StatPearls Publishing, 2025. [Online]. Available: Accessed: Jun. 16, 2025.
[17] National Cancer Institute, "Paget disease of the breast." [Online]. Available: Accessed: Oct. 2, 2022.
[18] National Organization for Rare Disorders, "Paget's disease of the breast." [Online]. Available: . Accessed: Oct. 2, 2022.